DOSSIER SENO 3

2946-06

- Patiente de 32 ans sans antécédent, allaitant son enfant depuis 18 mois
- Pas d'antécédent familial particulier
- Apparition d'une grosse masse dans la partie supérieure du sein D

R
Centre Alexis Vautrin
27/10/2006
15:19:28
P
L
L = 1437
W = 744

R
Centre Alexis Vautrin
27/10/2006
15:22:56
P
L
L = 1582
W = 806

2946-06

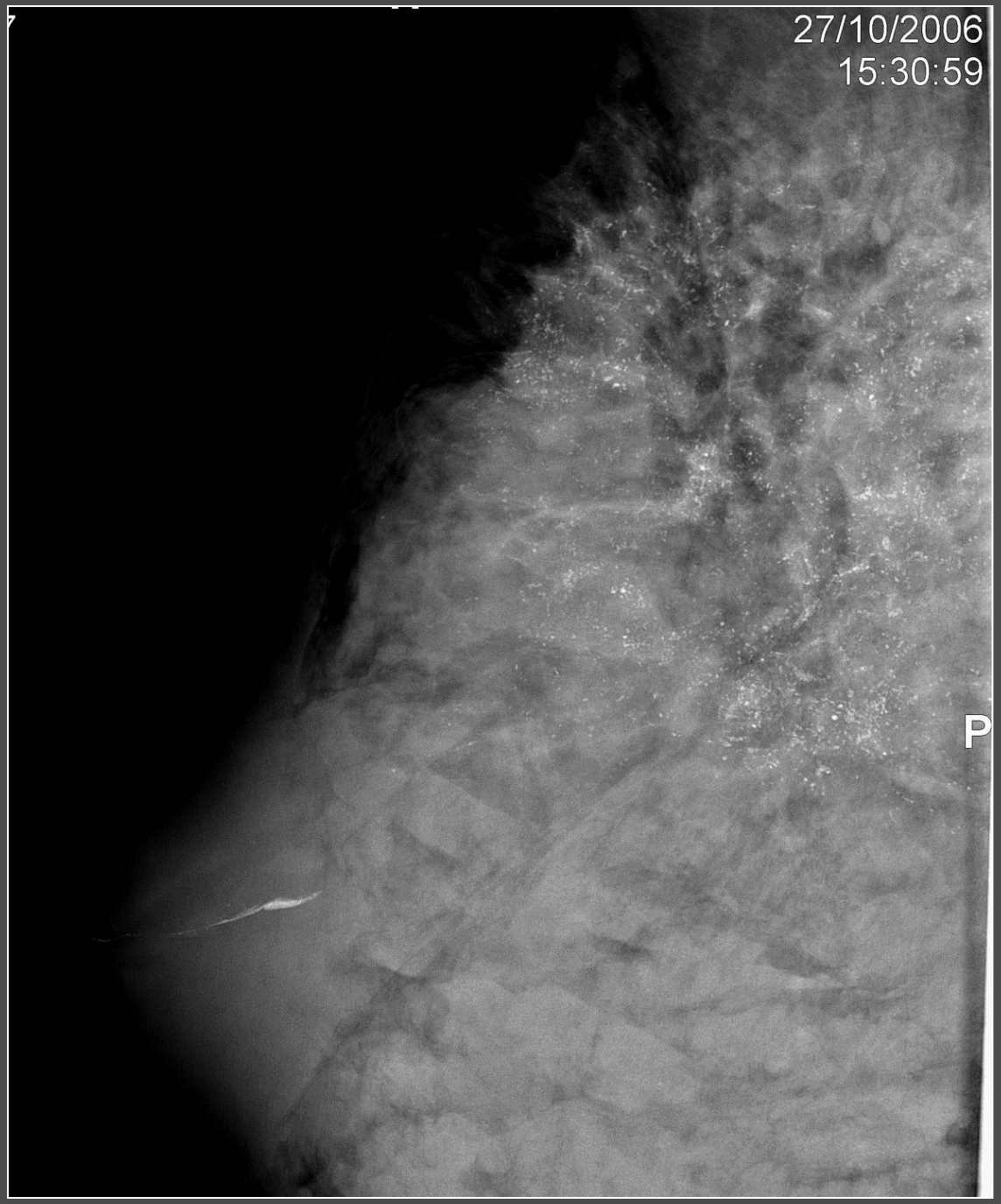

2946-06

2946-06

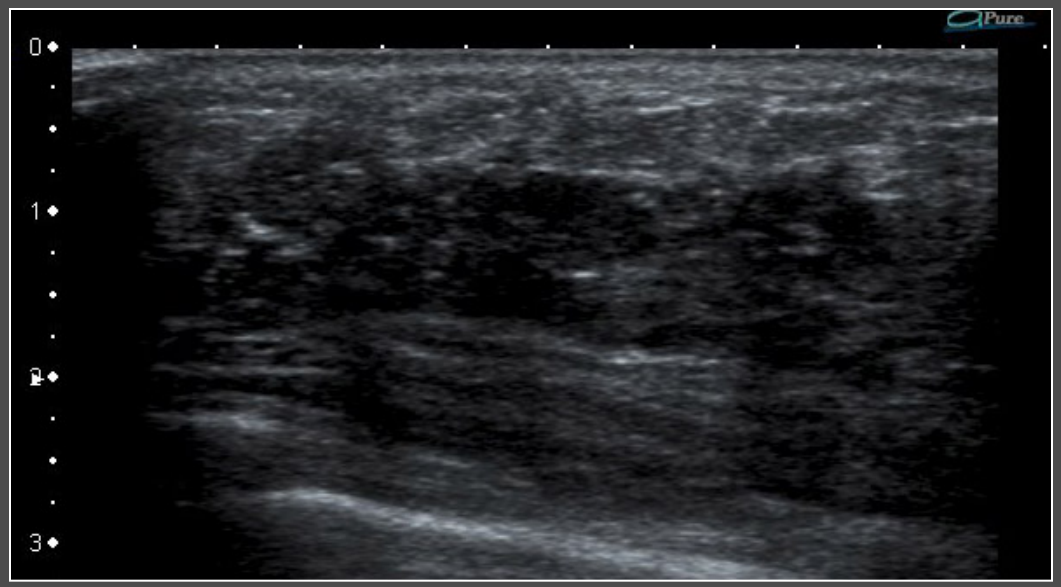

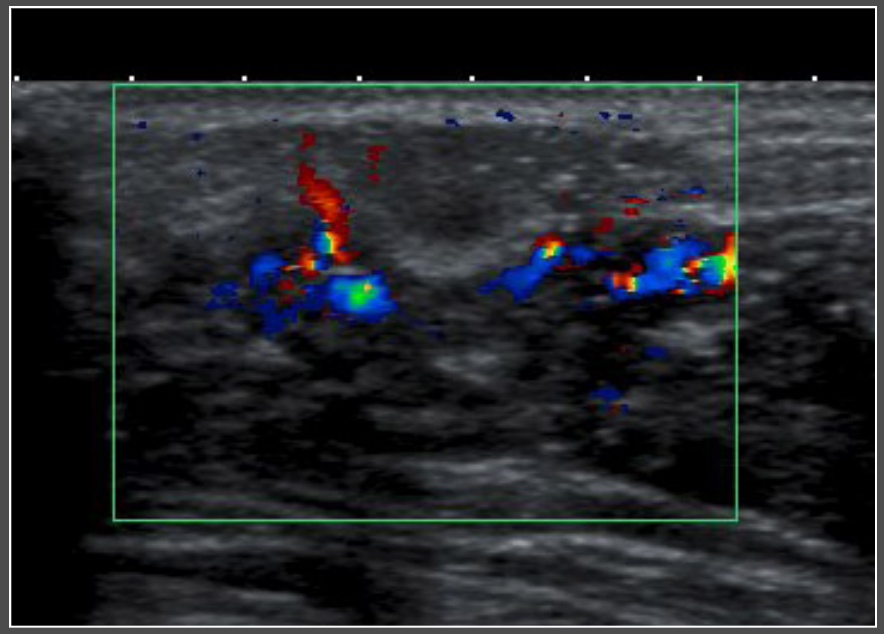

2983-05 Thouvenin

- DOSSIER JOURNEE CAROLUS

2983-05

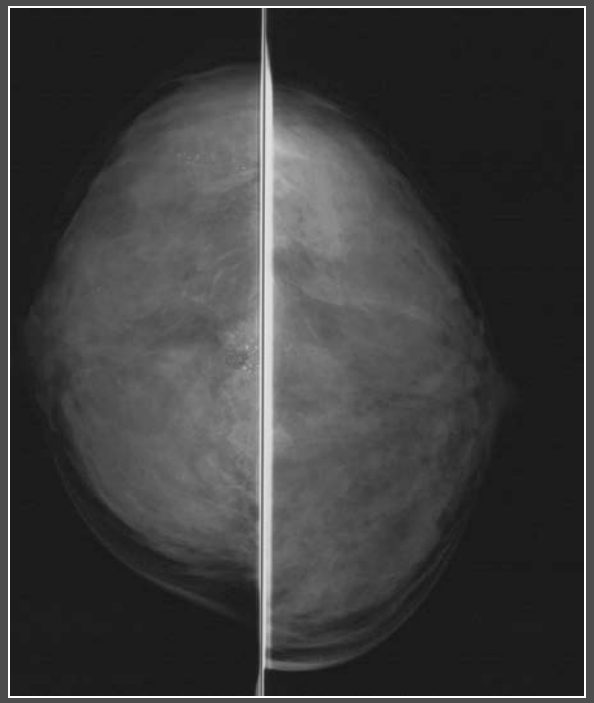

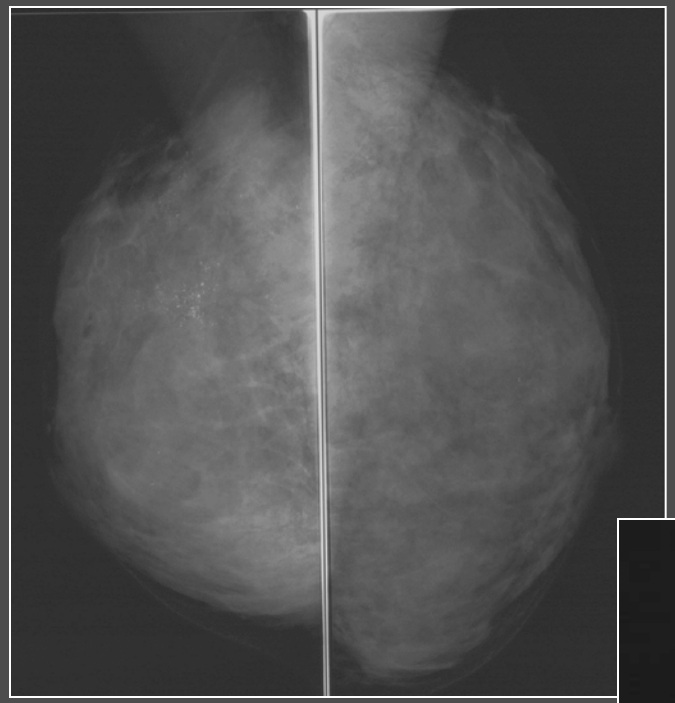

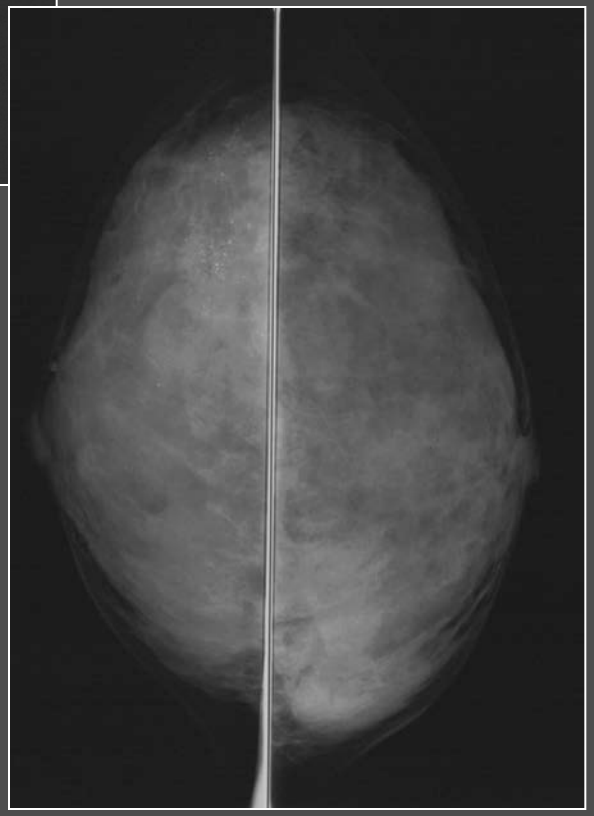

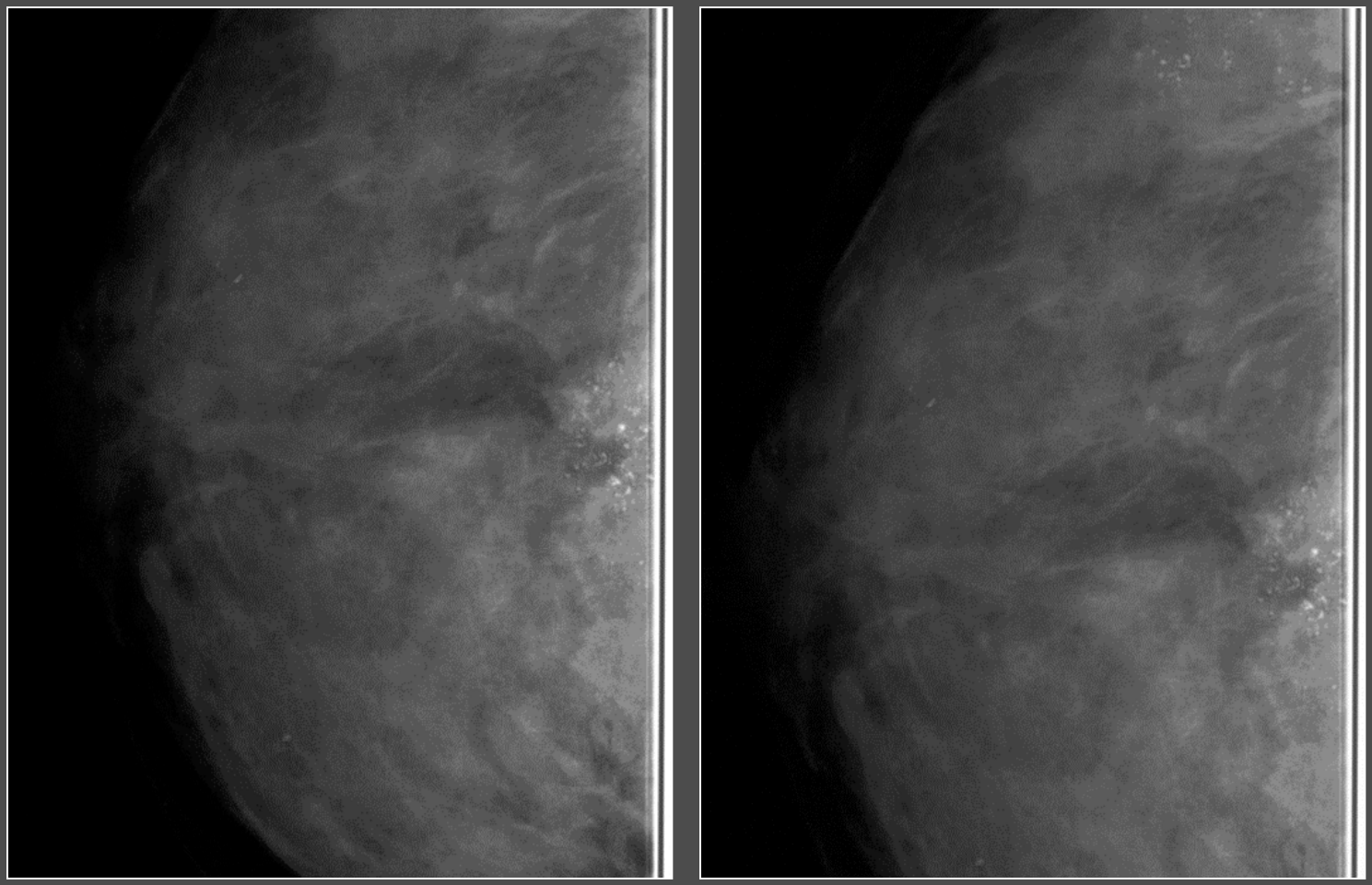

2983-05

2984-02

- Patiente de 38 ans sans antécédent familial de cancer du sein
- Densification dans la partie inférieure de son sein D

2984-02

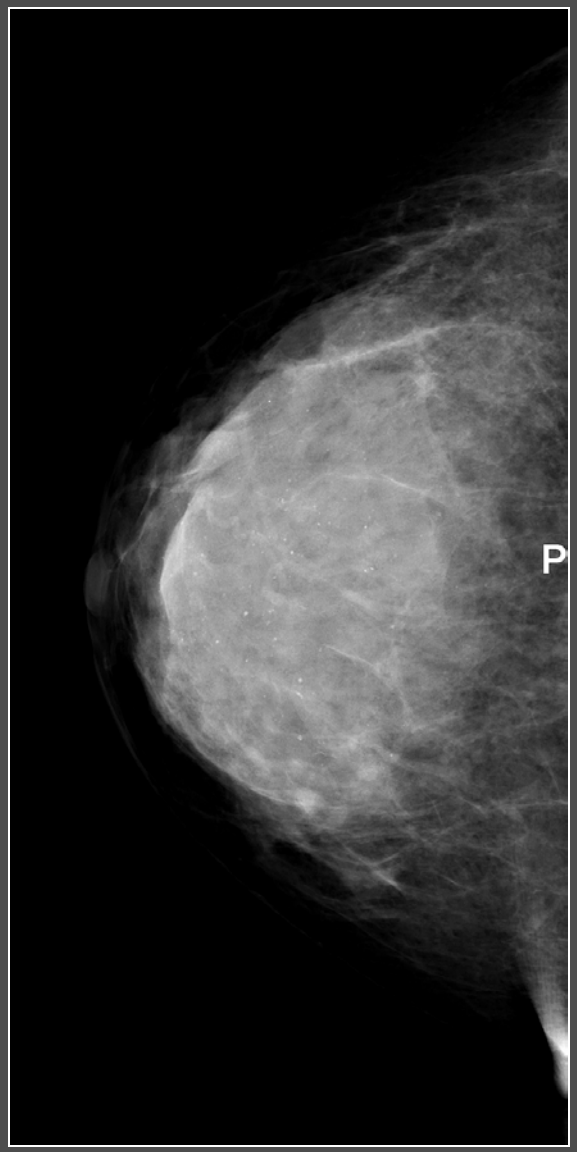
P

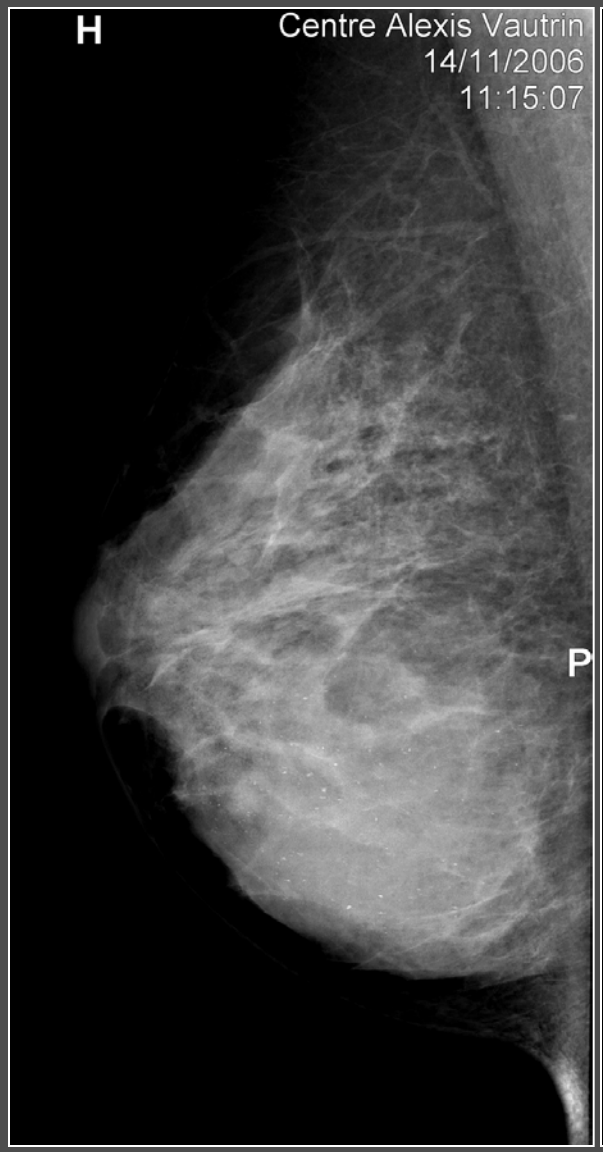
H
Centre Alexis Vautrin
14/11/2006
11:15:07
P

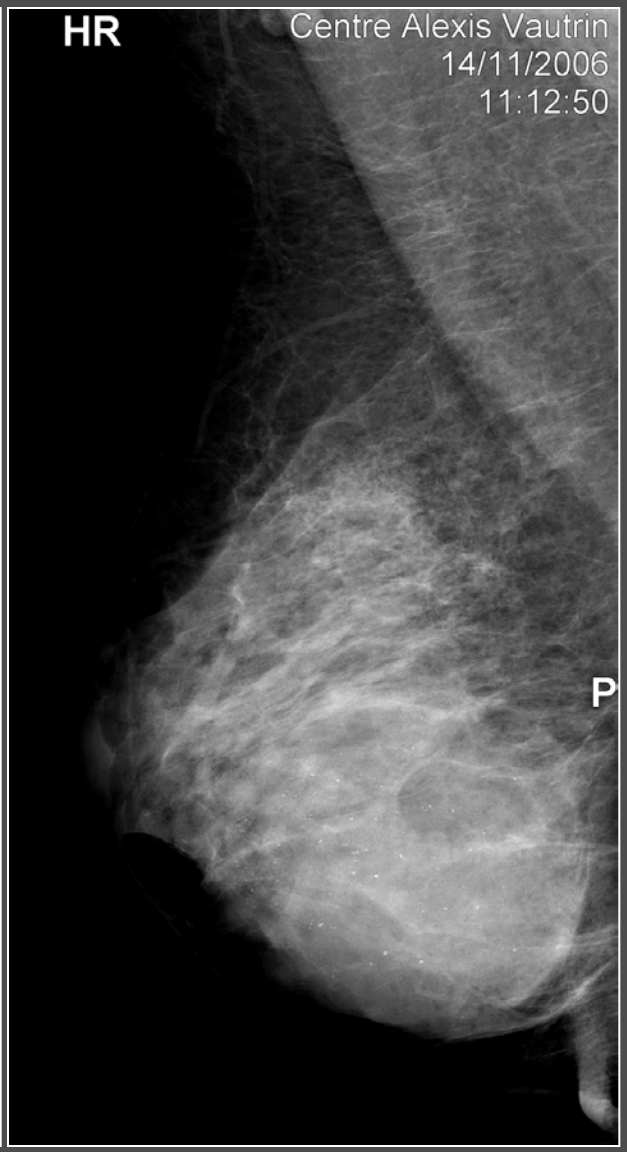
HR
Centre Alexis Vautrin
14/11/2006
11:12:50
P

2984-02

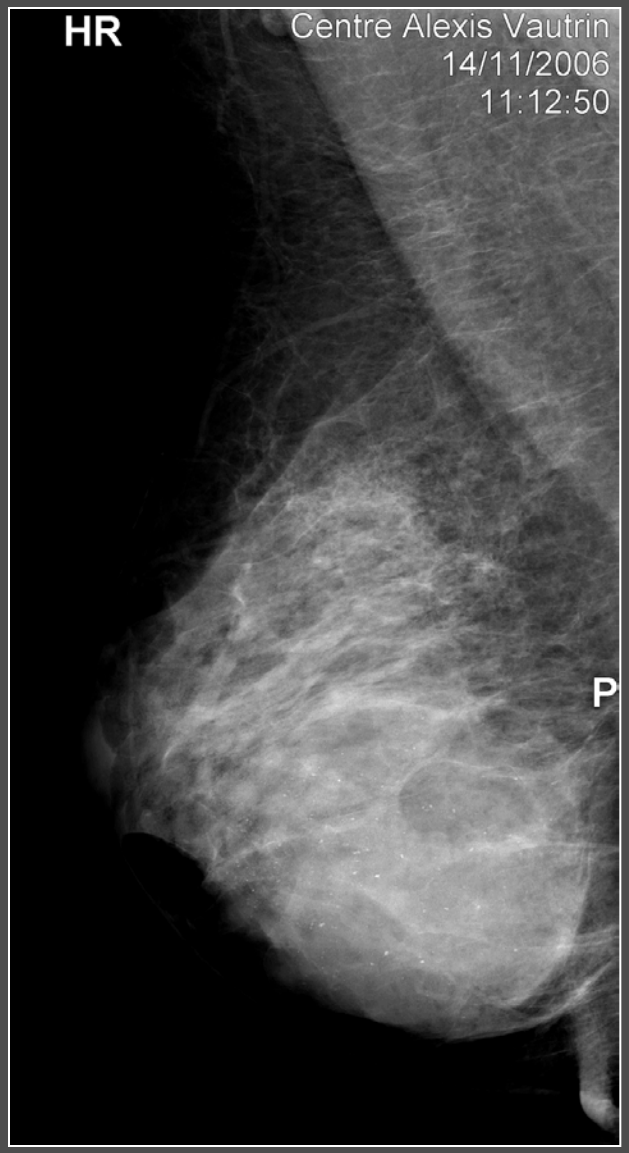

2984-02

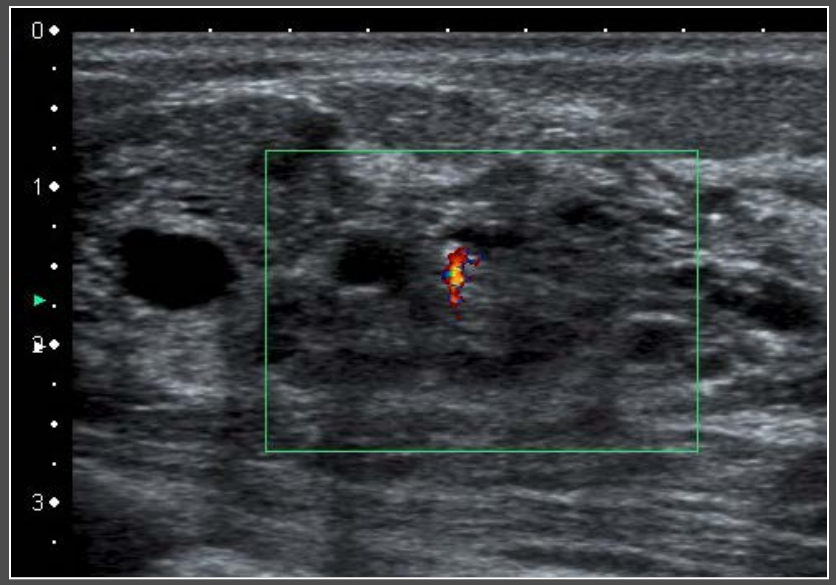

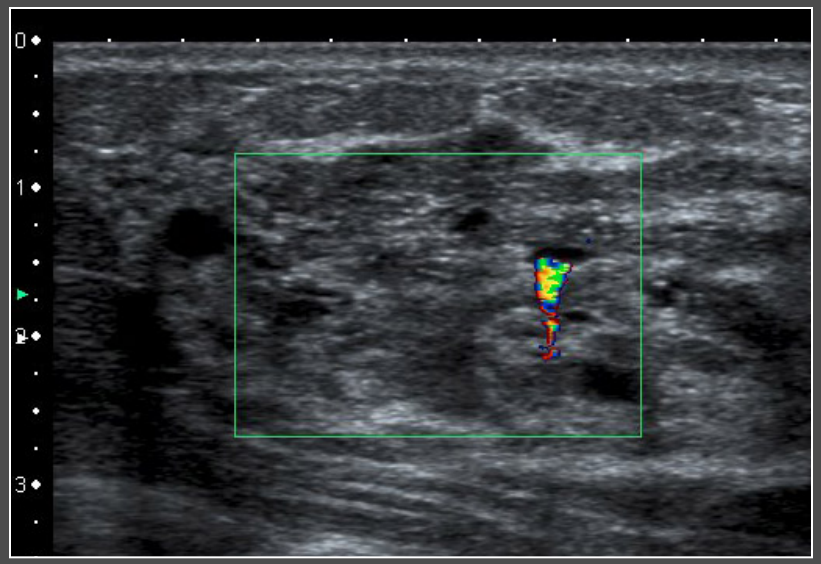

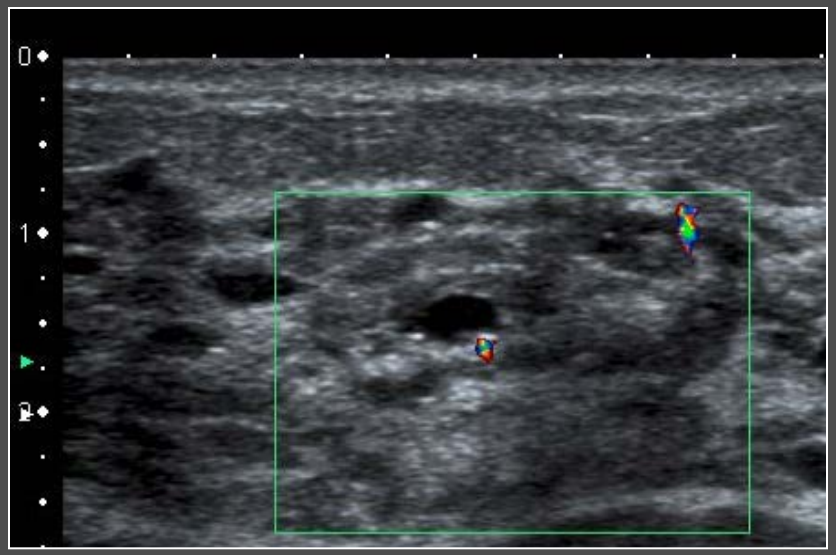

2984-02

Dilatations kystiques galactophoriques bénignes

Artefacts doppler liés aux calcifications

2710-04

- Patiente de 84 ans présentant une masse de 10 cm du QSExt du sein G

2710-04

Ex. 1
Se. 1
Im. 1
5
5
cm/s
SEIN G
KYSTE PARAMAM EXT
VERSANT EXT

SEIN G
KYSTE PARAMAM EXT
VERSANT SUP

2710-04

Carcinome papillaire intra-kystique de grade intermédiaire de 4 cm

2728-06

- Patiente de 42 ans sans antécédent familial de cancer du sein
- Microcalcifications rétro-mamelonnaires du sein G

2728-06

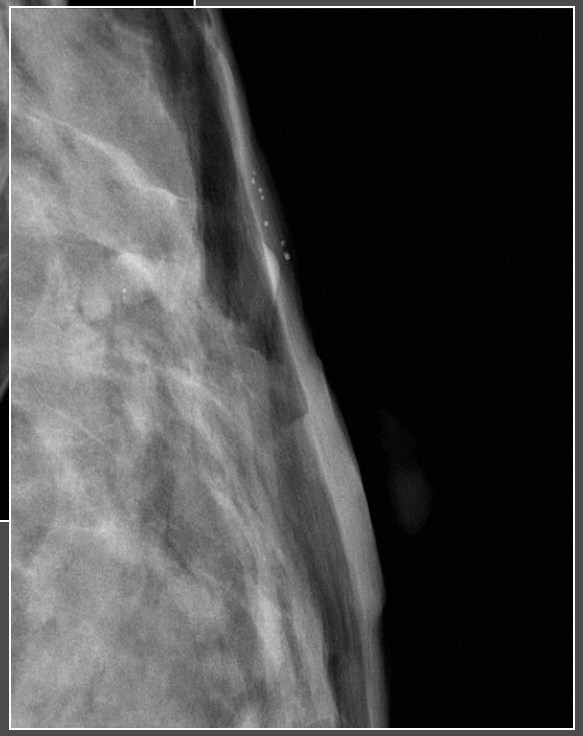

2728-06

Microcalcifications cutanées

566-98

- Patiente de 65 ans
- Mammographie de dépistage
- Pas d'antécédent particulier
- Examen clinique mammaire normal

566-98

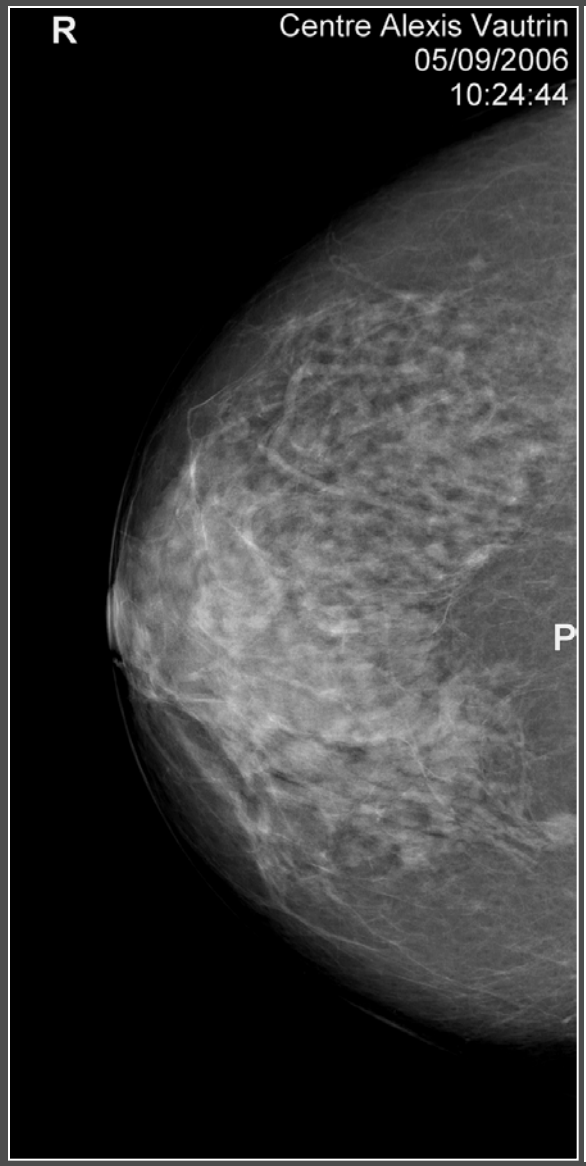
R
Centre Alexis Vautrin
05/09/2006
10:24:44
P

HR
Centre Alexis Vautrin
05/09/2006
10:28:10
P

H
Centre Alexis Vautrin
05/09/2006
10:31:37
P

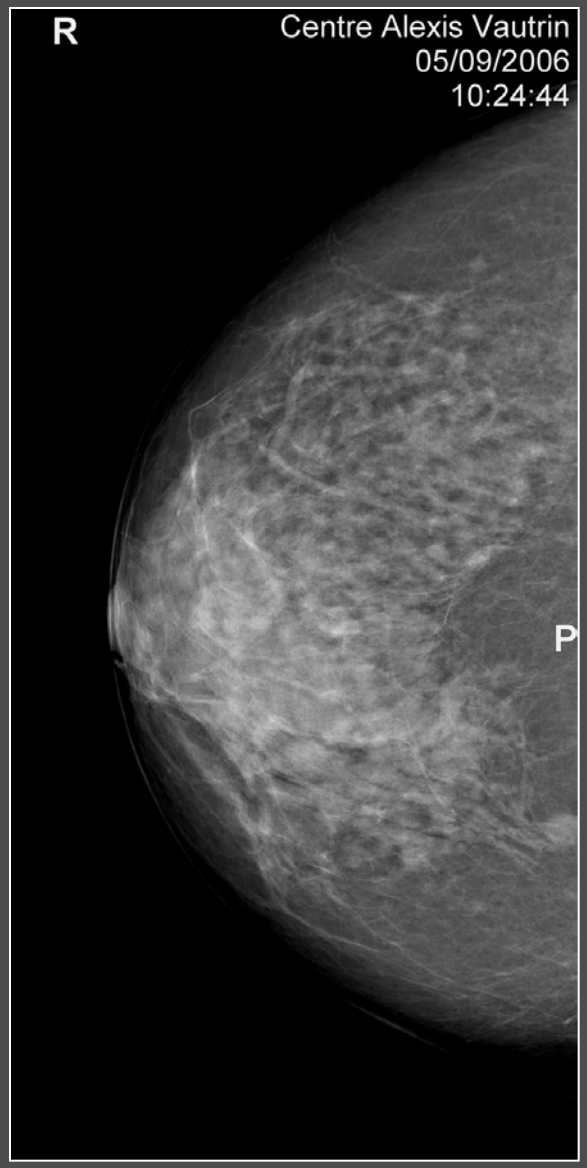

566-98

Cliché centré

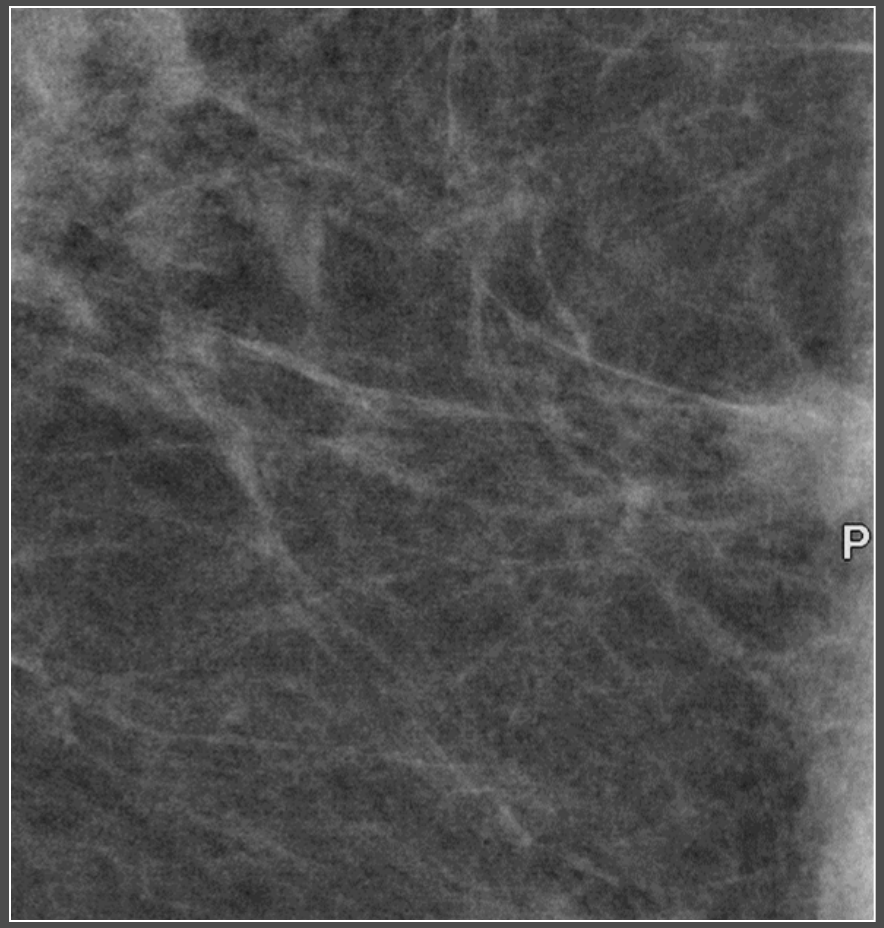

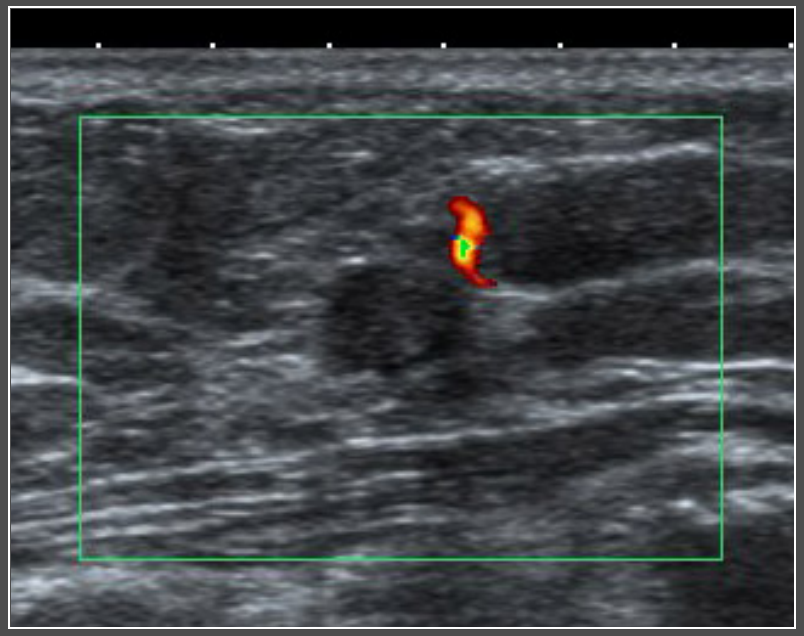

Cliché centré après repérage préalable de la lésion en échographie

566-98

566-98

Carcinome mammaire D prouvé par microbiopsies

2125-06

- Patiente de 87 ans, découverte à l'occasion du bilan d'un cancer colique d'une tumeur étendue du sein G avec adénopathies axillaire

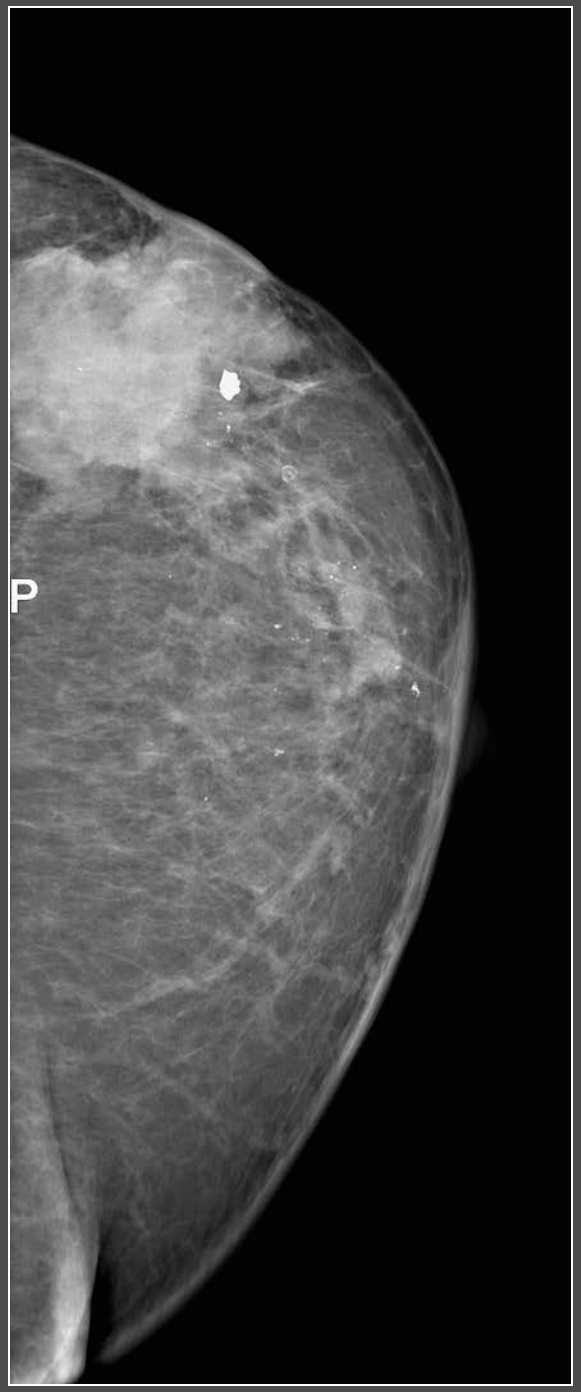

2125-06

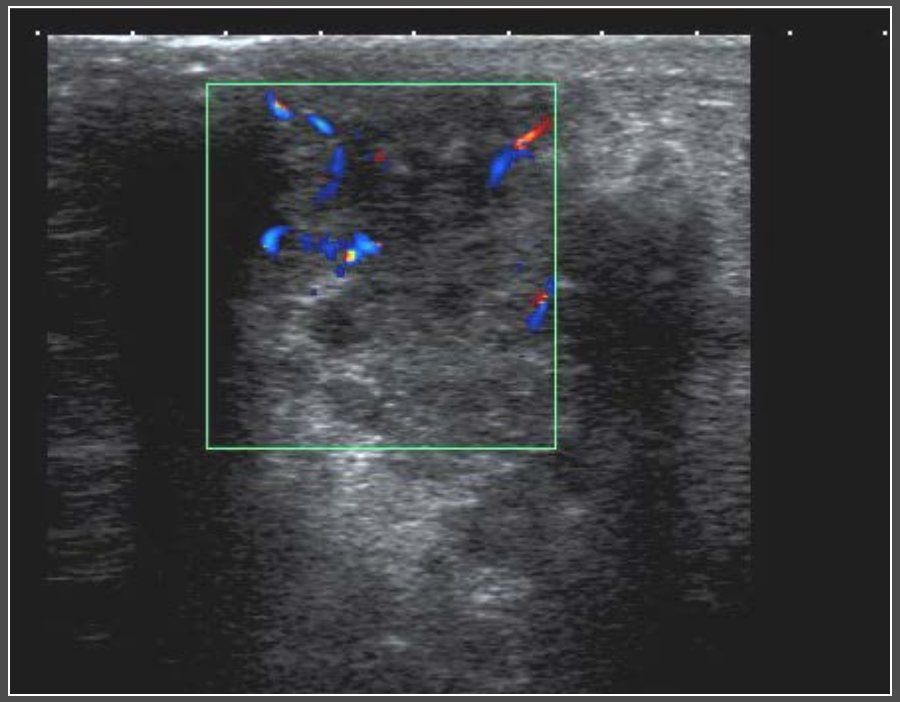

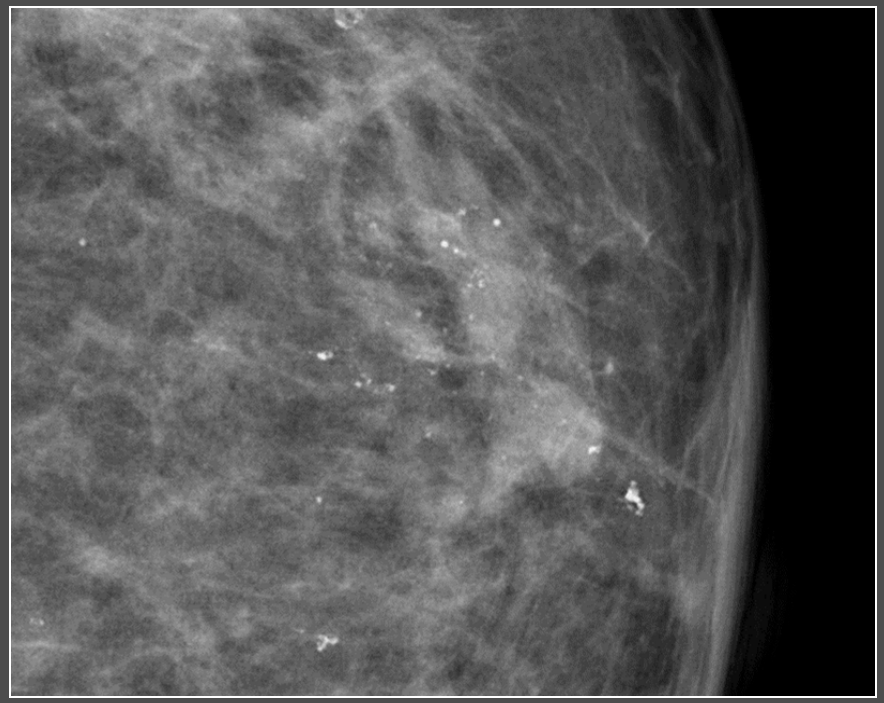

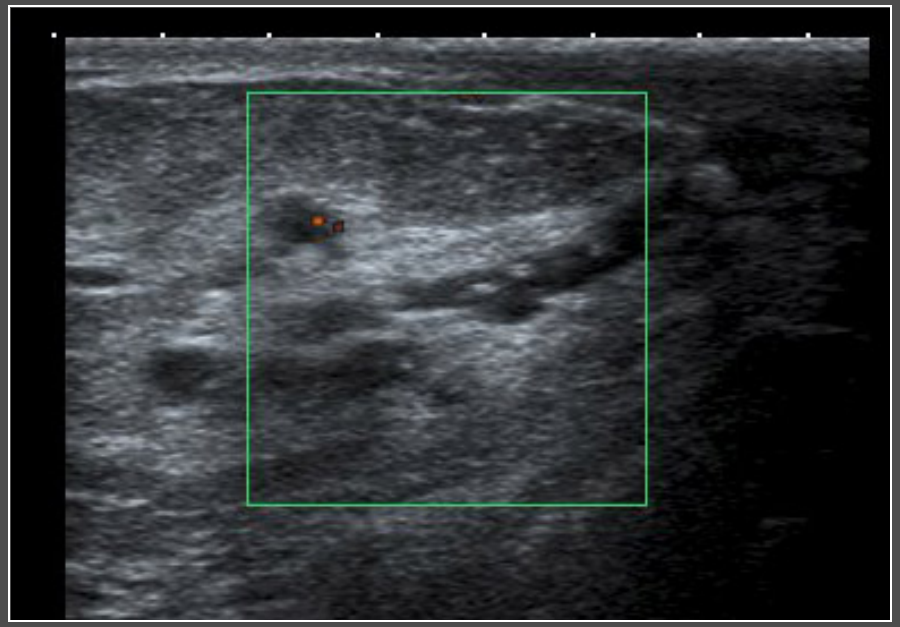

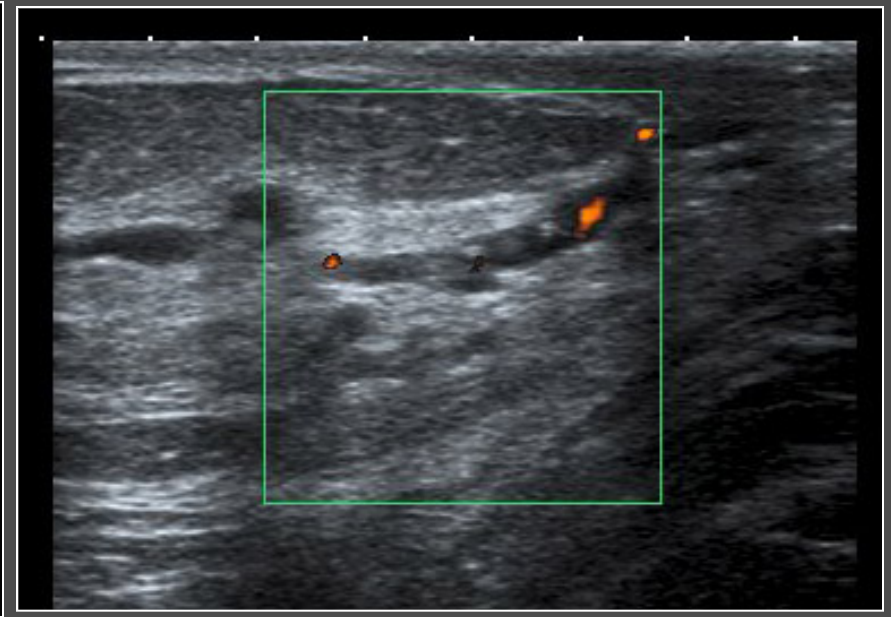

2125-06

2125-06

Carcinome avec extension galactophorique vers le mamelon

1693-94

1693-94

H
Centre Alexis Vautrin
26/08/2005
15:26:54
P
F
L = 2048
W = 4096

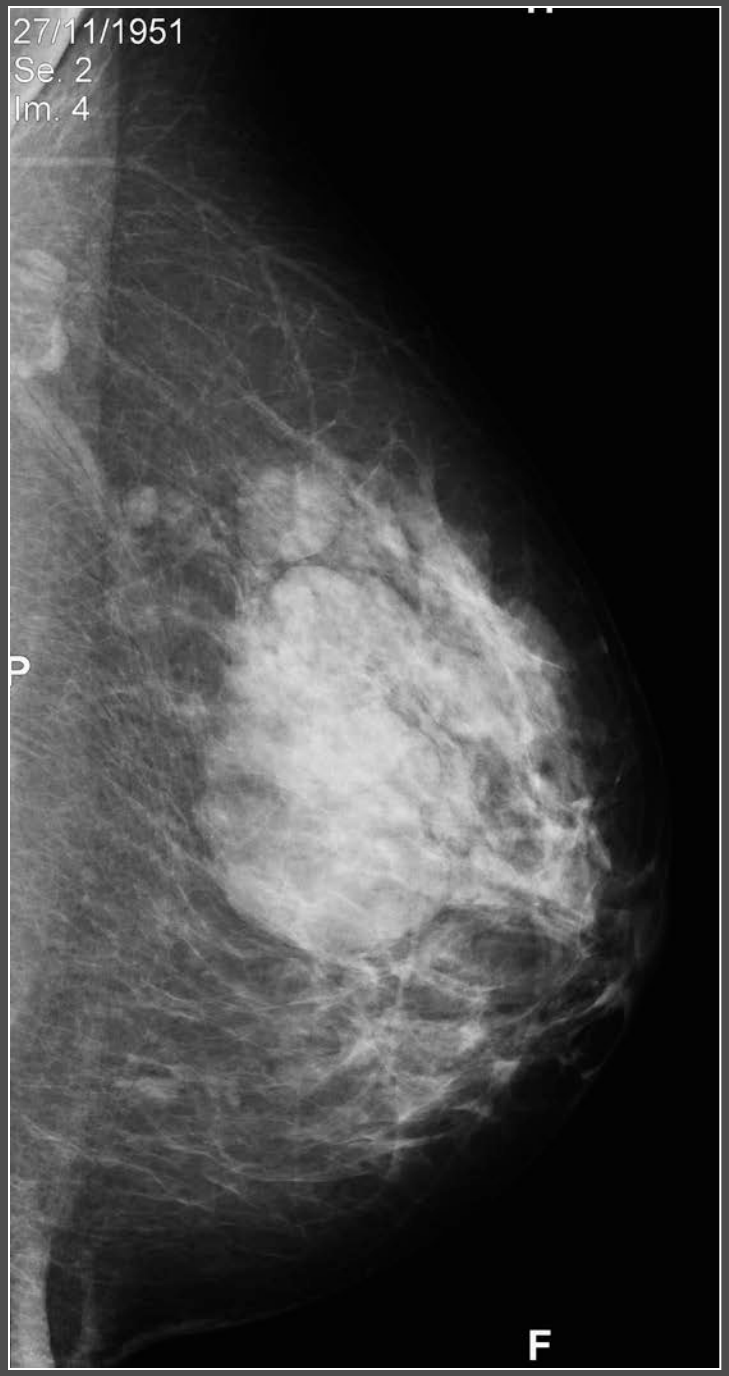
27/11/1951
Se. 2
Im. 4
P
F

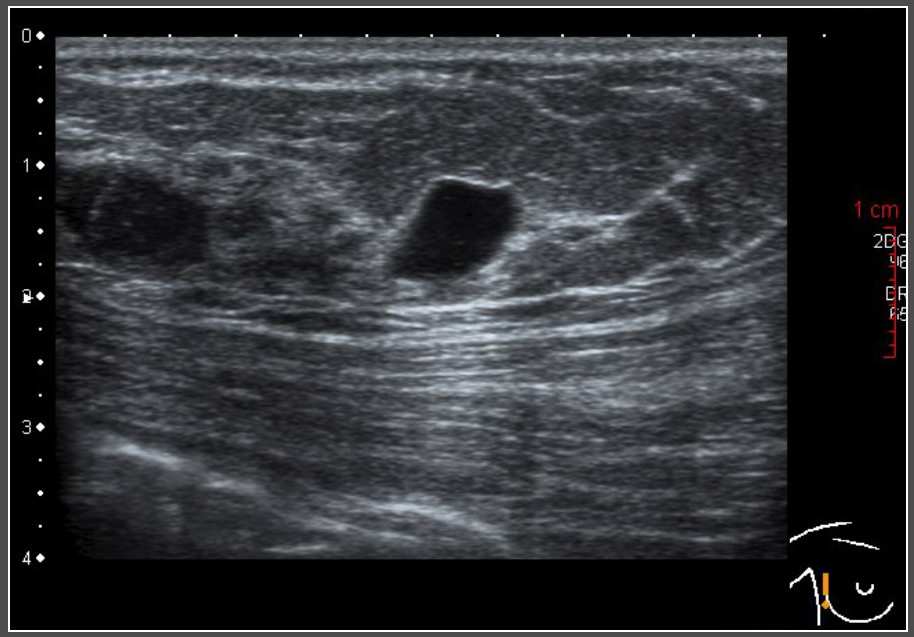

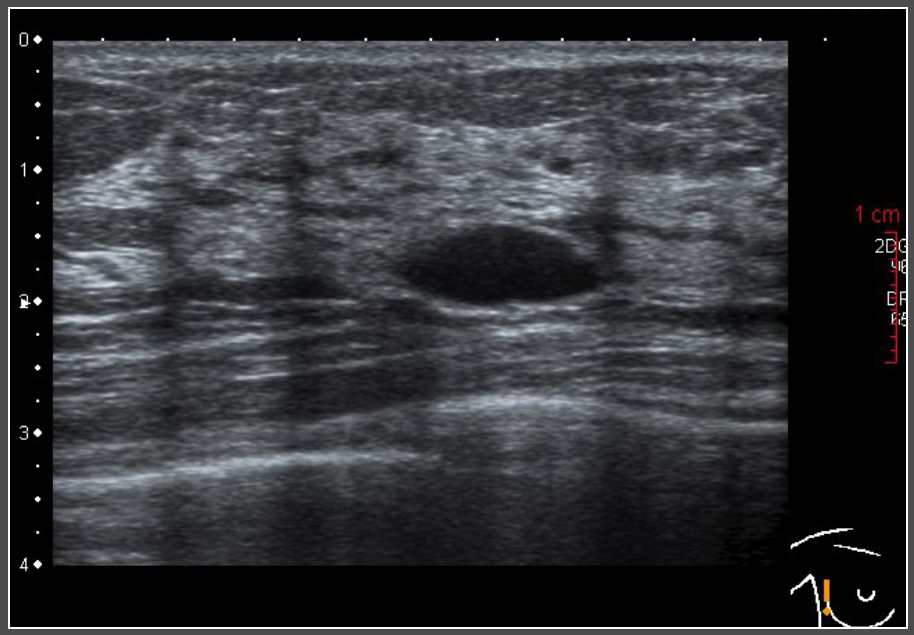

1693-94 D

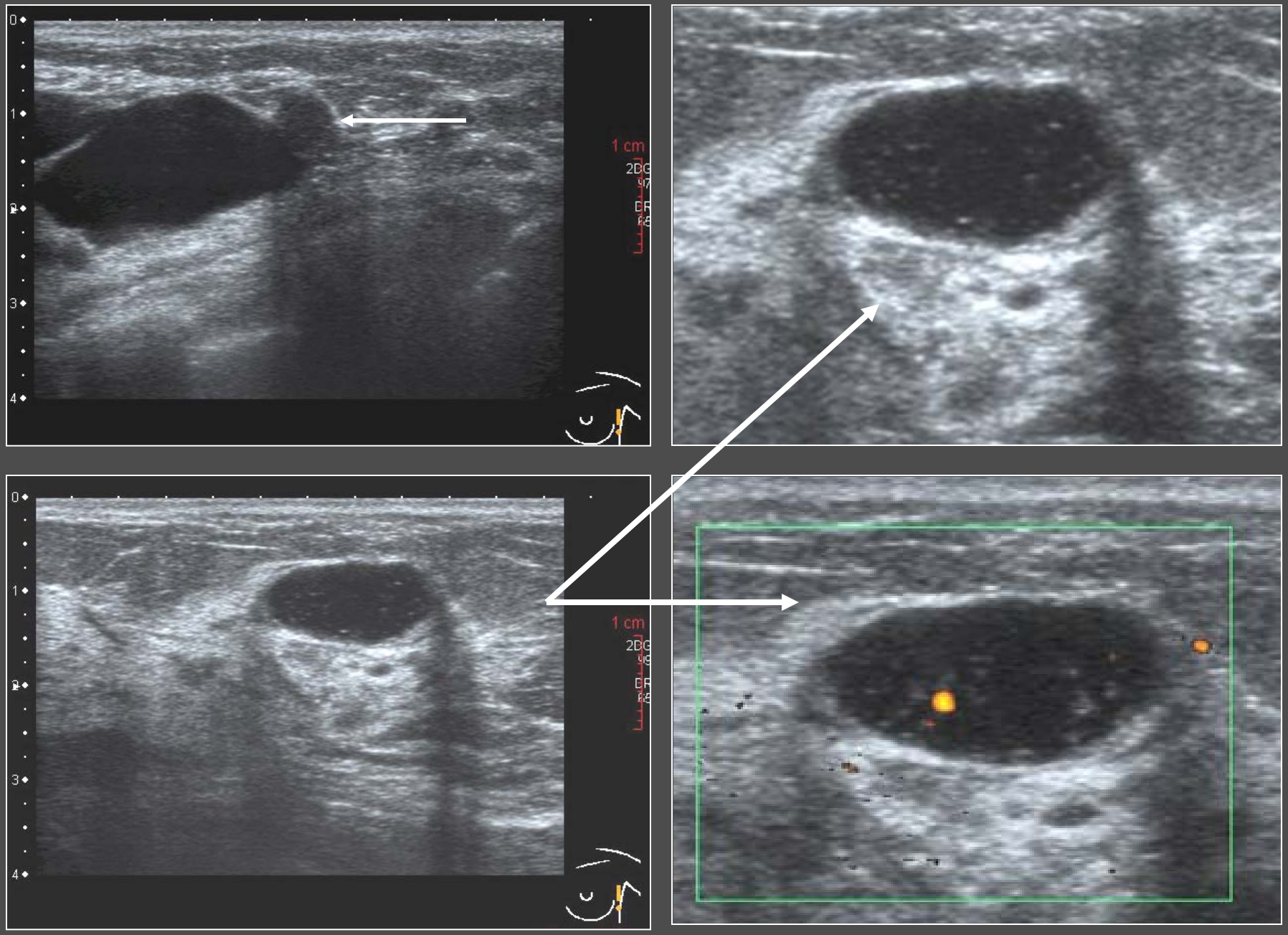

1693-94 G

MFK

Kystes à contenu épais

1975-06

- Patiente de 56 ans
- THS depuis 7 ans
- Anomalie infra-clinique échographique du sein G (cytologie et micro-biopsies négatifs)
- Examen clinique normal
- Demande d'avis complémentaire

1975-06

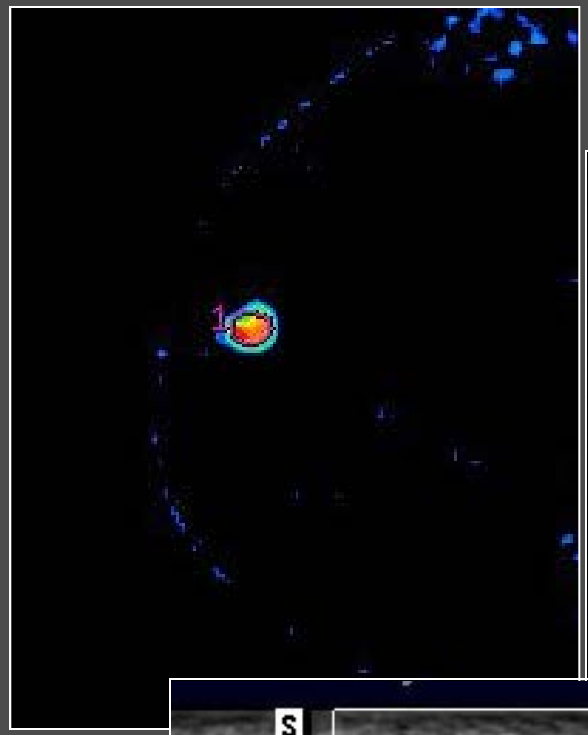

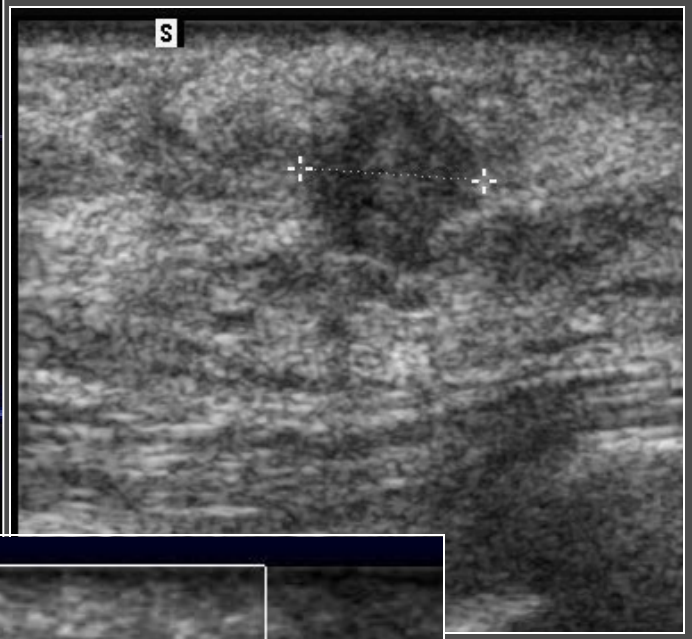

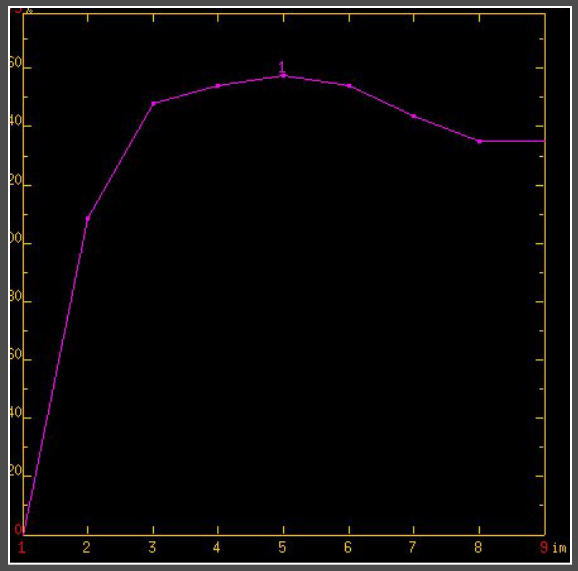

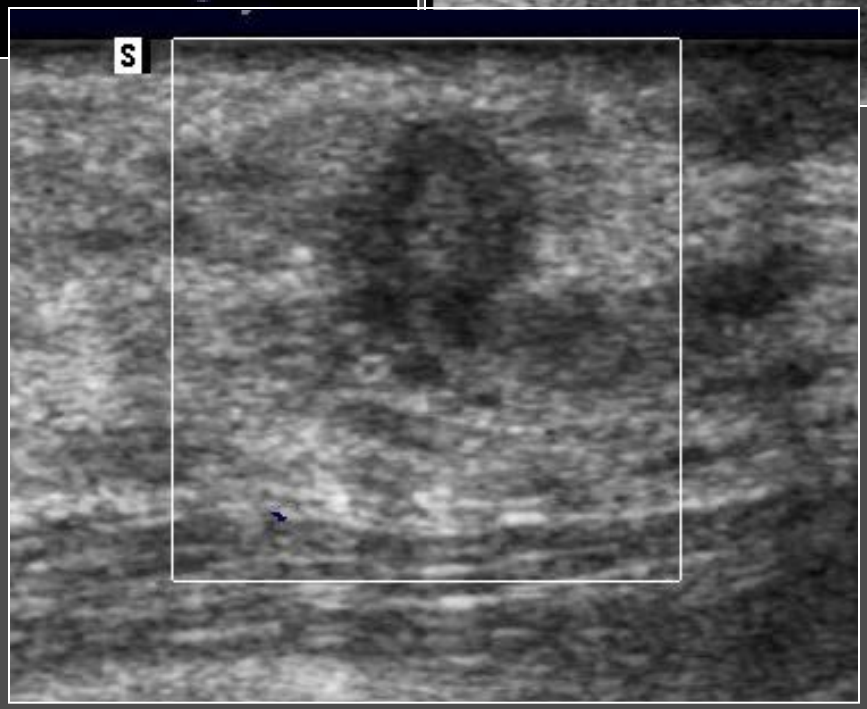

1754-06

- Lésion fibreuse avec des ectasies galactophoriques et remaniements inflammatoires post ponction
- Absence de malignité

1754-06

1754-06

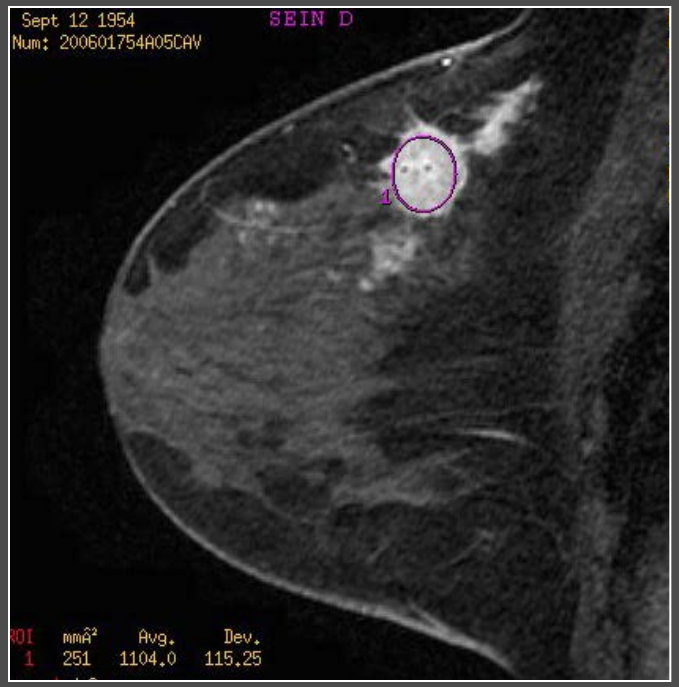
Sept 12 1954
SEIN D
Num: 200601754A05CAV
ROI mmÂ² Avg. Dev.
1 251 1104.0 115.25

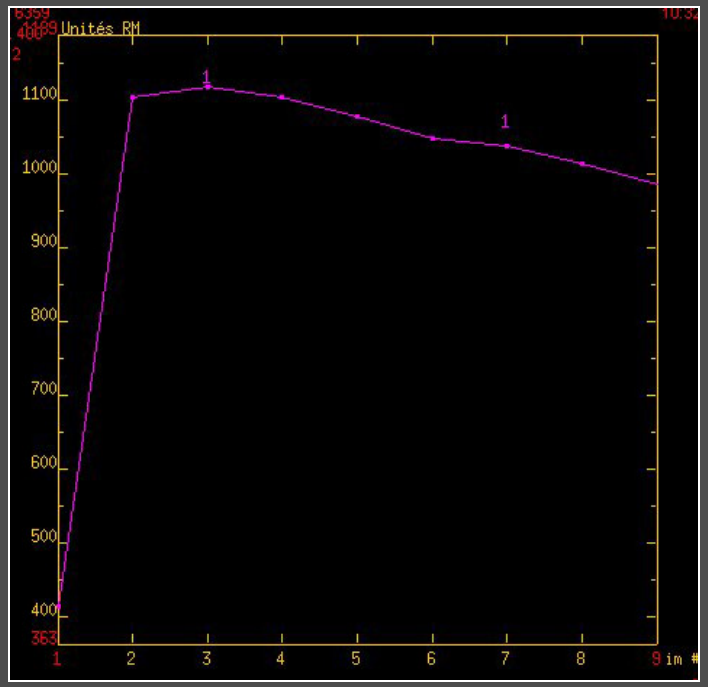
Unités RM
1100
1000
900
800
700
600
500
400
1 2 3 4 5 6 7 8 9 im #

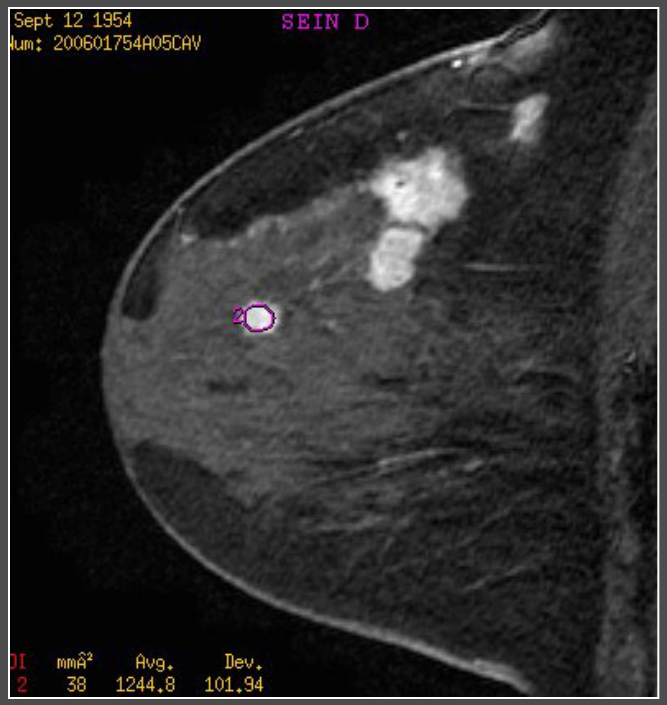
Sept 12 1954
SEIN D
Num: 200601754A05CAV
ROI mmÂ² Avg. Dev.
2 38 1244.8 101.94

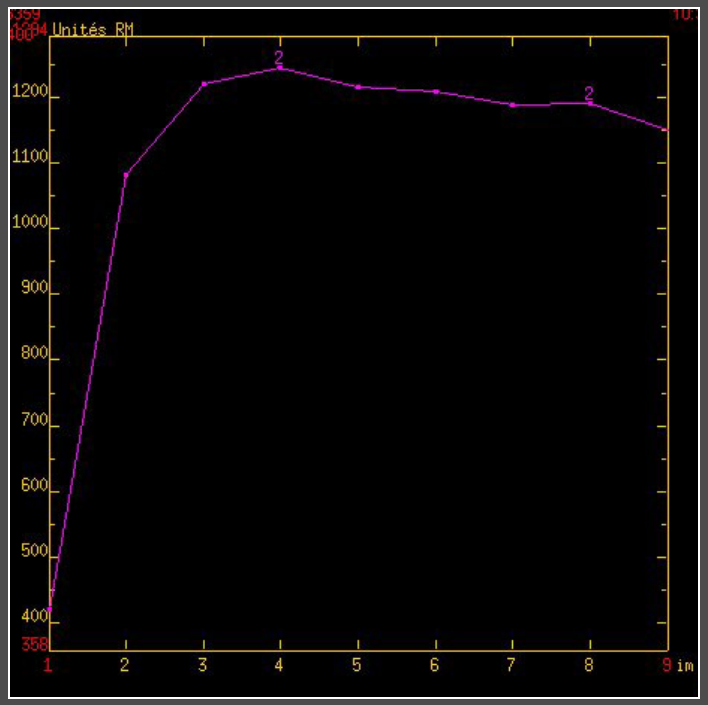
Unités RM
1200
1100
1000
900
800
700
600
500
400
1 2 3 4 5 6 7 8 9 im

2301-06

- Patiente de 60 ans
- 8 ans de THS (arrêté récemment)
- Cousine maternelle ayant fait un carcinome mammaire
- Microcalcifications bifocales du Q S Ext du sein G d'apparition récente
- Echographie mammaire normale

2301-06

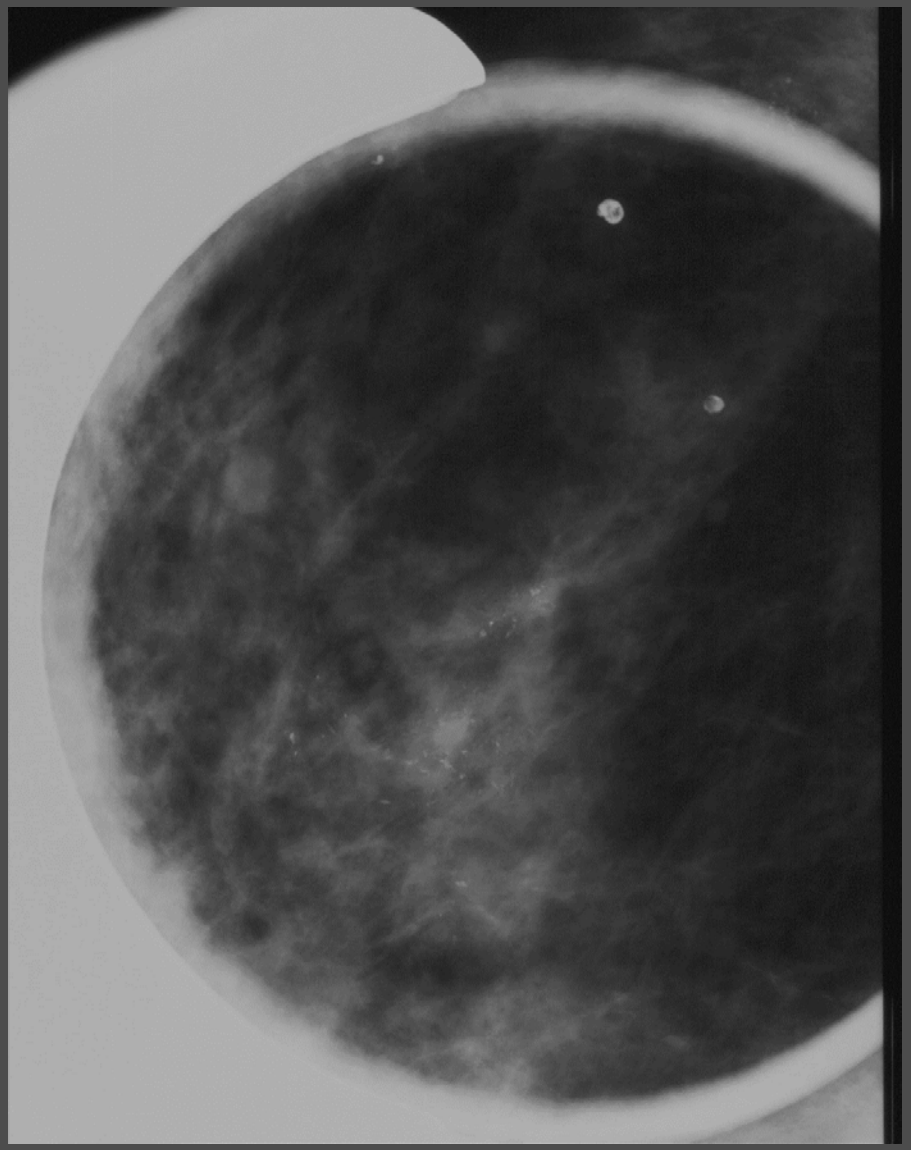

2301-06

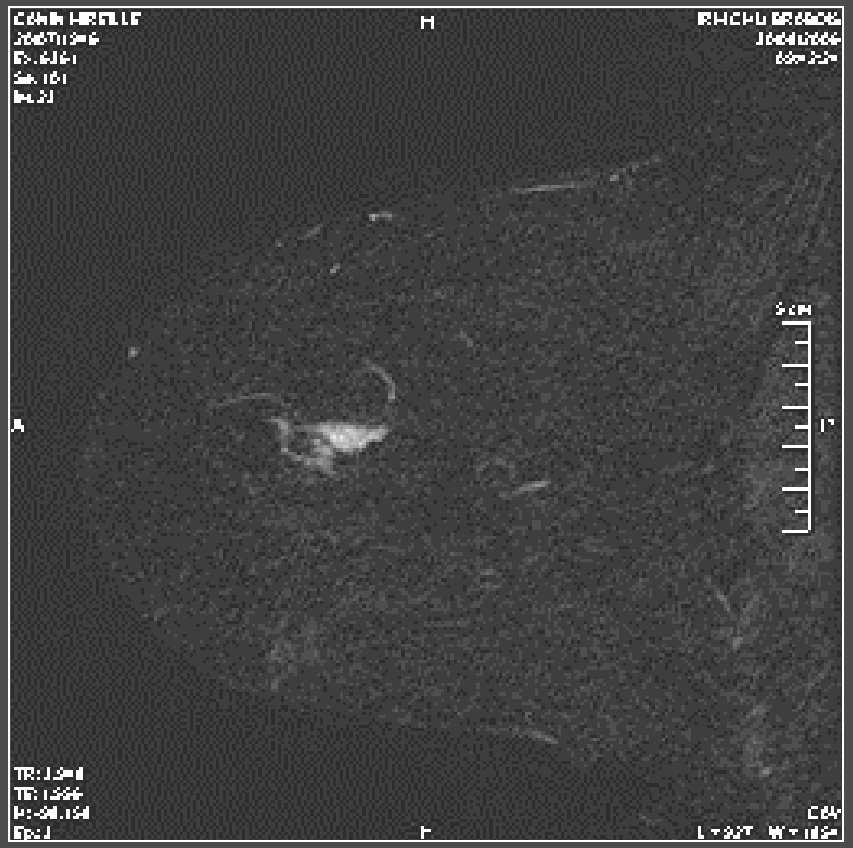

2301-06

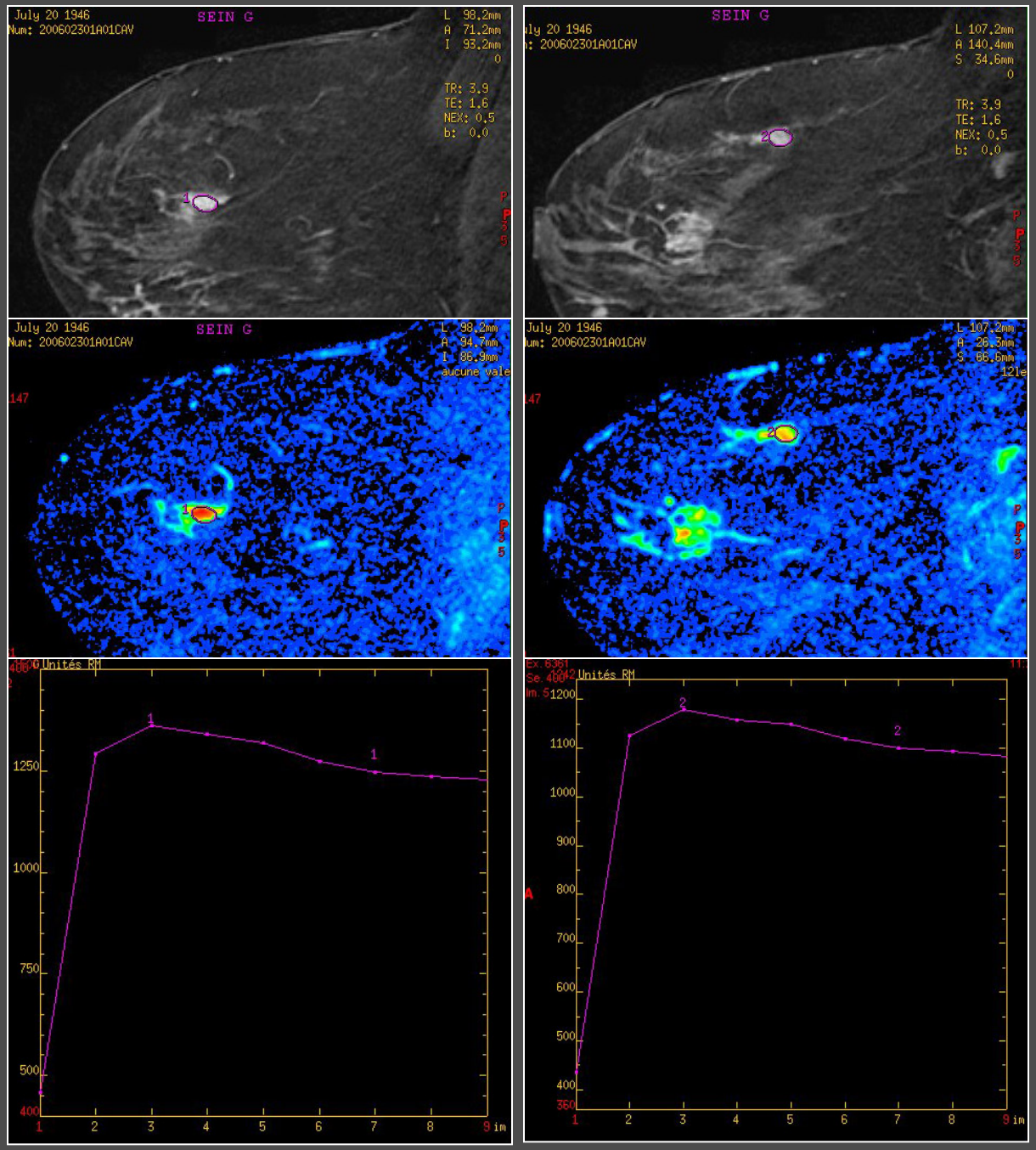
July 20 1946
Num: 200602301A01CAV
SEIN G
L 98.2mm
A 71.2mm
I 93.2mm
TR: 3.9
TE: 1.6
NEX: 0.5
b: 0.0
L 107.2mm
A 140.4mm
S 34.6mm
L 98.2mm
A 94.7mm
I 86.9mm
aucune vale
L 107.2mm
A 26.3mm
S 86.6mm
121e
147
Unités RM
1250
1000
750
500
400
1200
1100
900
800
700
600
350
1 2 3 4 5 6 7 8 9 im

2301-06

Macro biopsies après l'IRM : CCI et nb foyers de CCIS de haut grade avec nécrose

Mastectomie G : CCI de 1,5x1,1x0,5cm
CCIS sur plus de 2cm avec micro infiltration
Pas d'envahissement ggl

2199-06

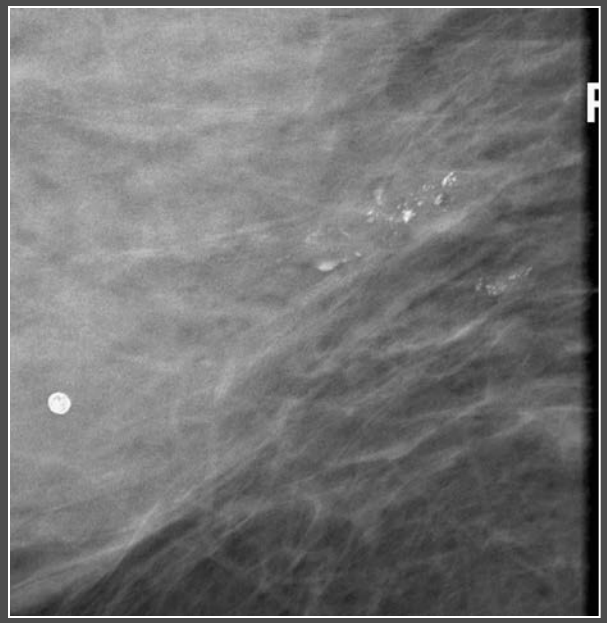

CC

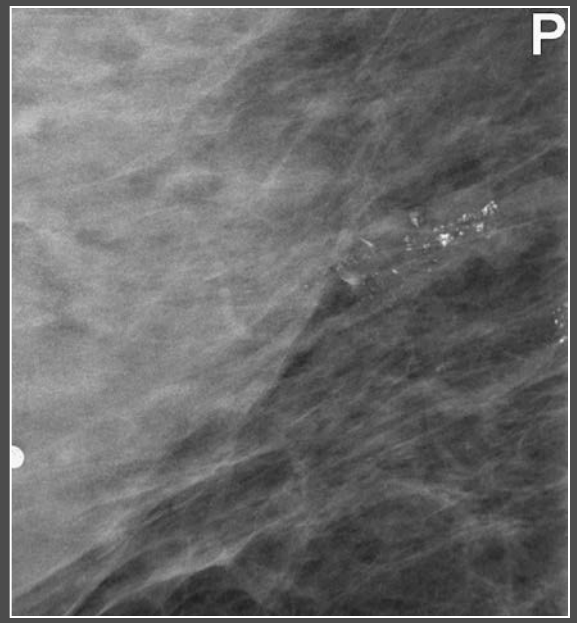

Oblique

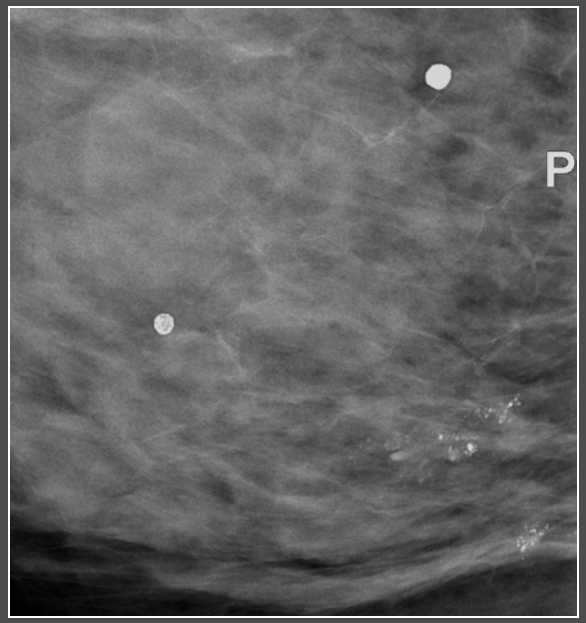

Latéral

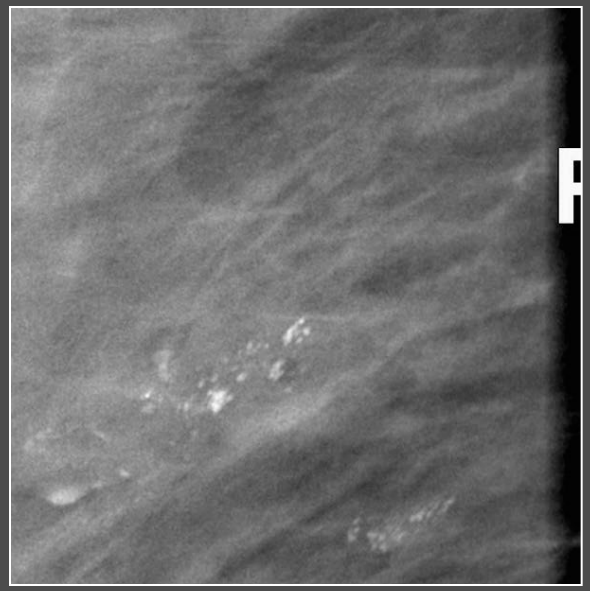

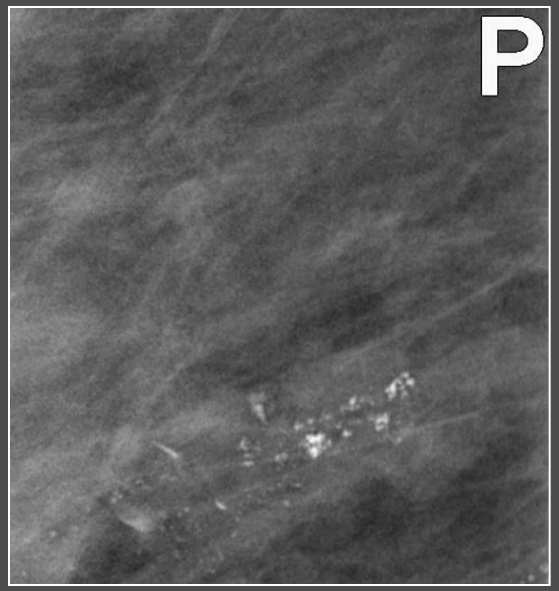

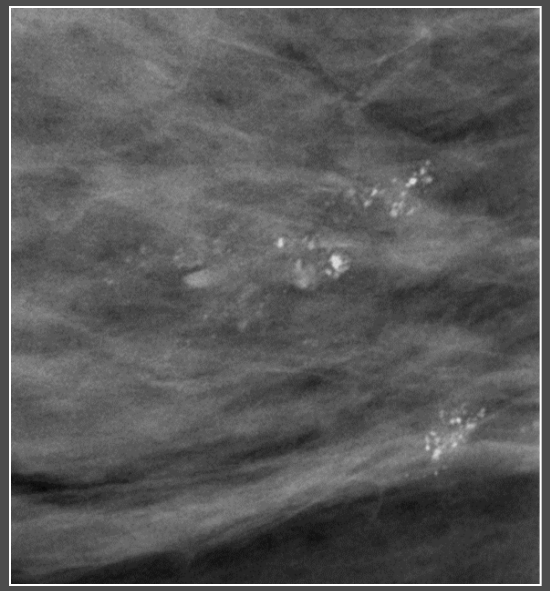

2199-06

2199-06

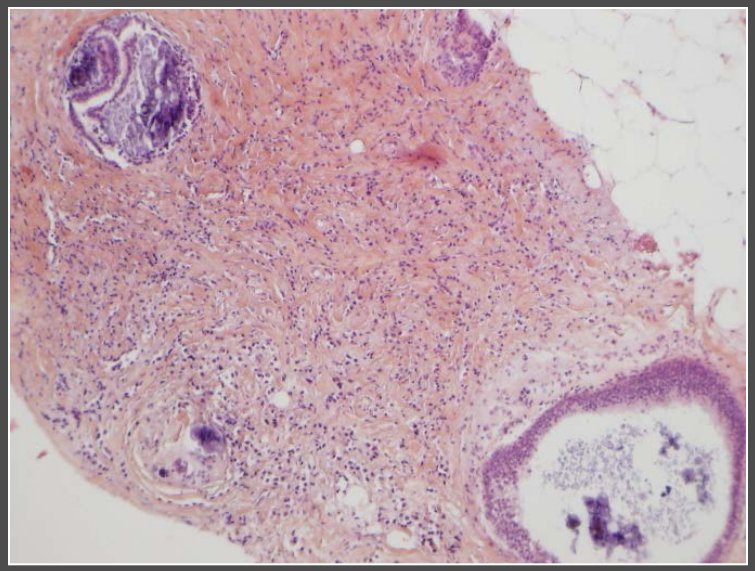

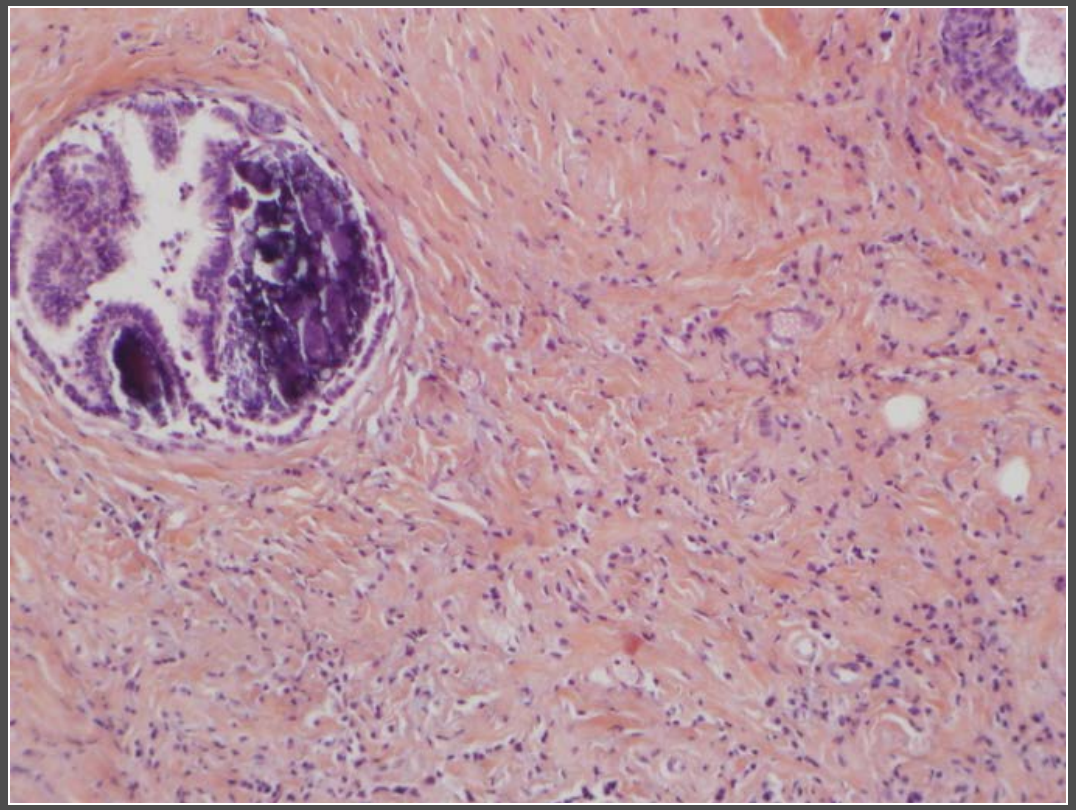

Carcinome lobulaire invasif associé à
des calcifications bénignes dans de
la métaplasie cylindrique non atypique

1789-76

- Patiente de 50 ans
- Suivi d'un mélanome du pouce
- Examen clinique normal
- Apparition d'une masse supérieure du sein G

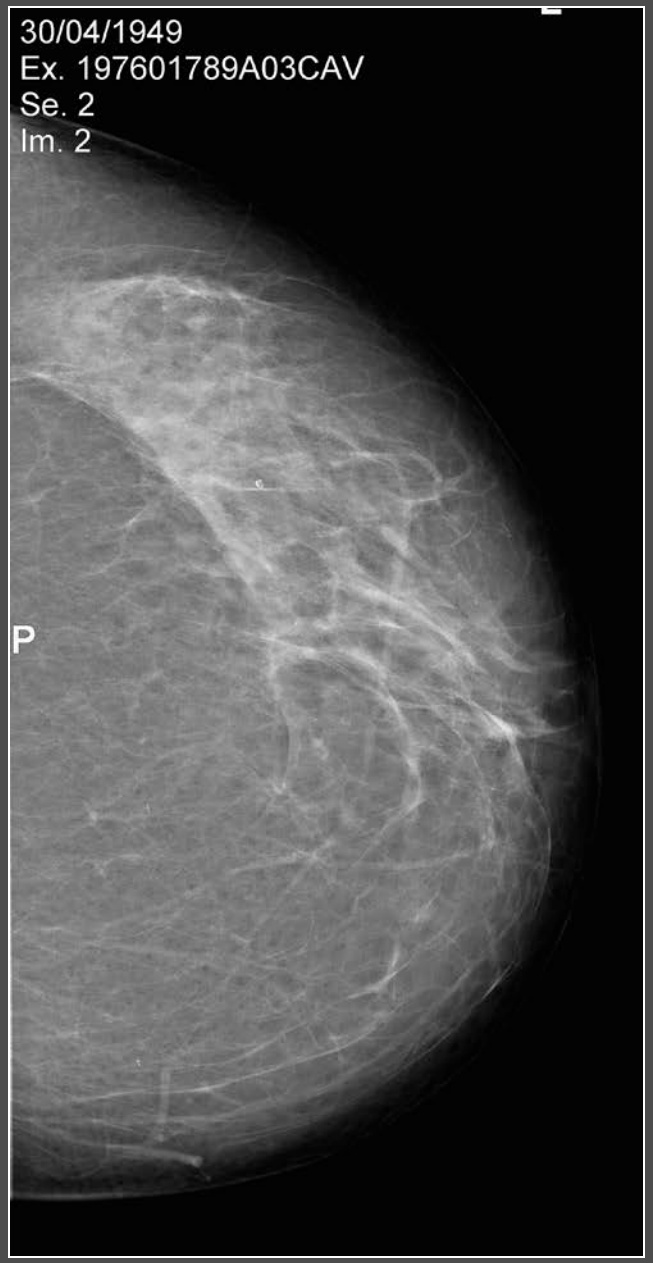
30/04/1949
Ex. 197601789A03CAV
Se. 2
Im. 2
P

30/04/1949
Ex. 197601789A03CAV
Se. 2
Im. 7
P

1789-76

1789-76

1789-76

Localisation ganglionnaire intra-mammaire d'une LLC

1761-04

- Patiente née en 1952 et traitée en 2004 pour un carcinome mammaire D
- Surveillance systématique et constatation d'une surdensité supéro-externe associée à une anomalie d'architecture minime
- Echographie négative
- Contrôle à 6 mois : anomalie radiologique stable mais présence d'une lacune en échographie

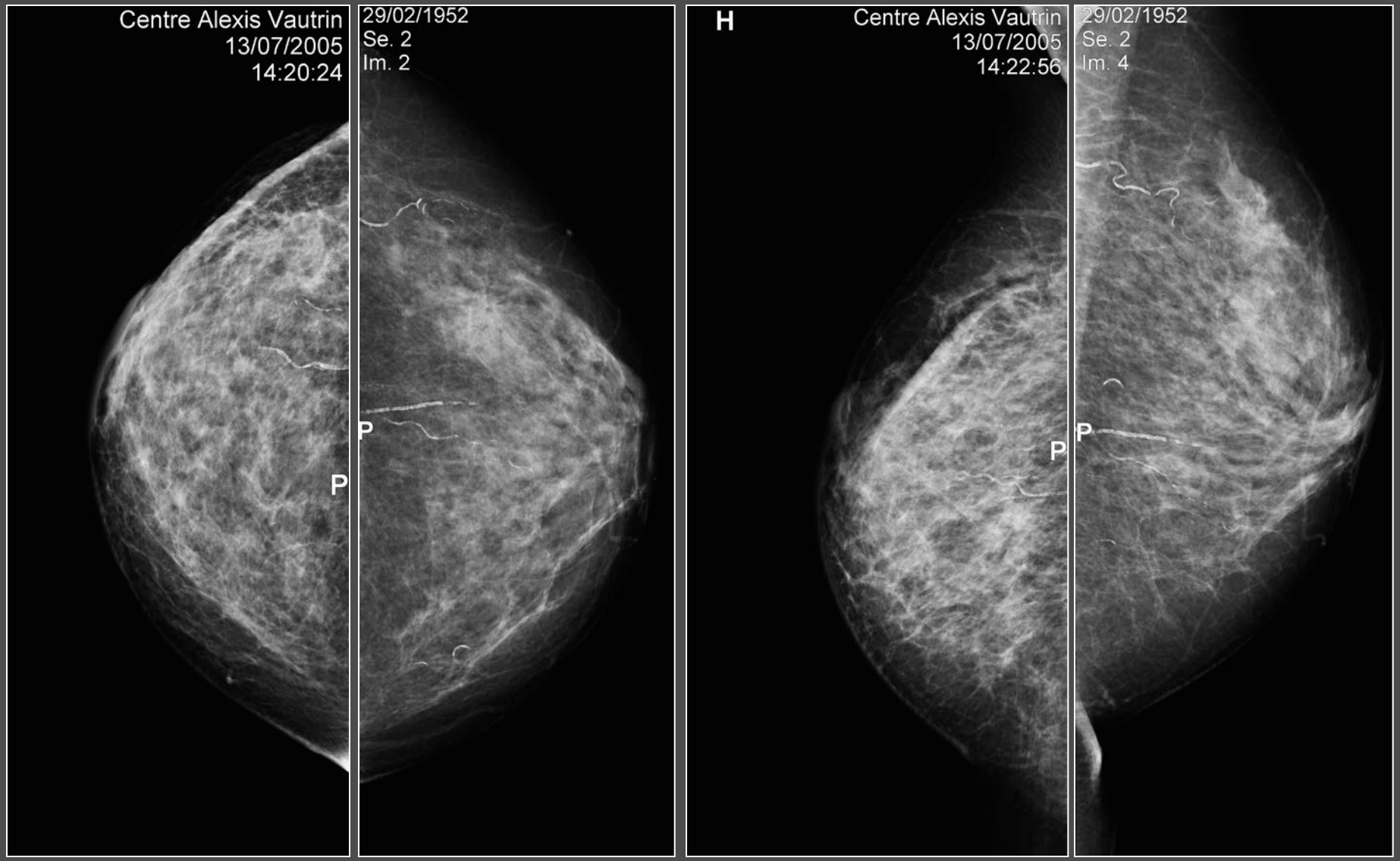
Centre Alexis Vautrin
13/07/2005
14:20:24
P
29/02/1952
Se. 2
Im. 2
P
H
Centre Alexis Vautrin
13/07/2005
14:22:56
P
29/02/1952
Se. 2
Im. 4
P

1761-04

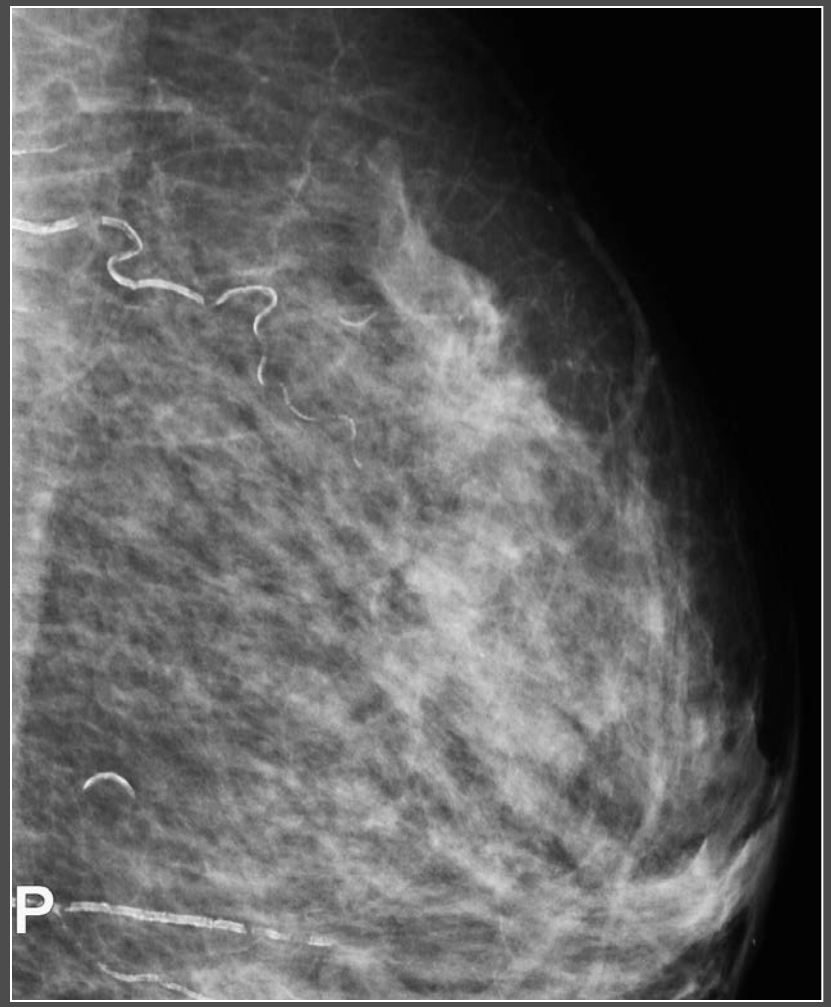

1761-04

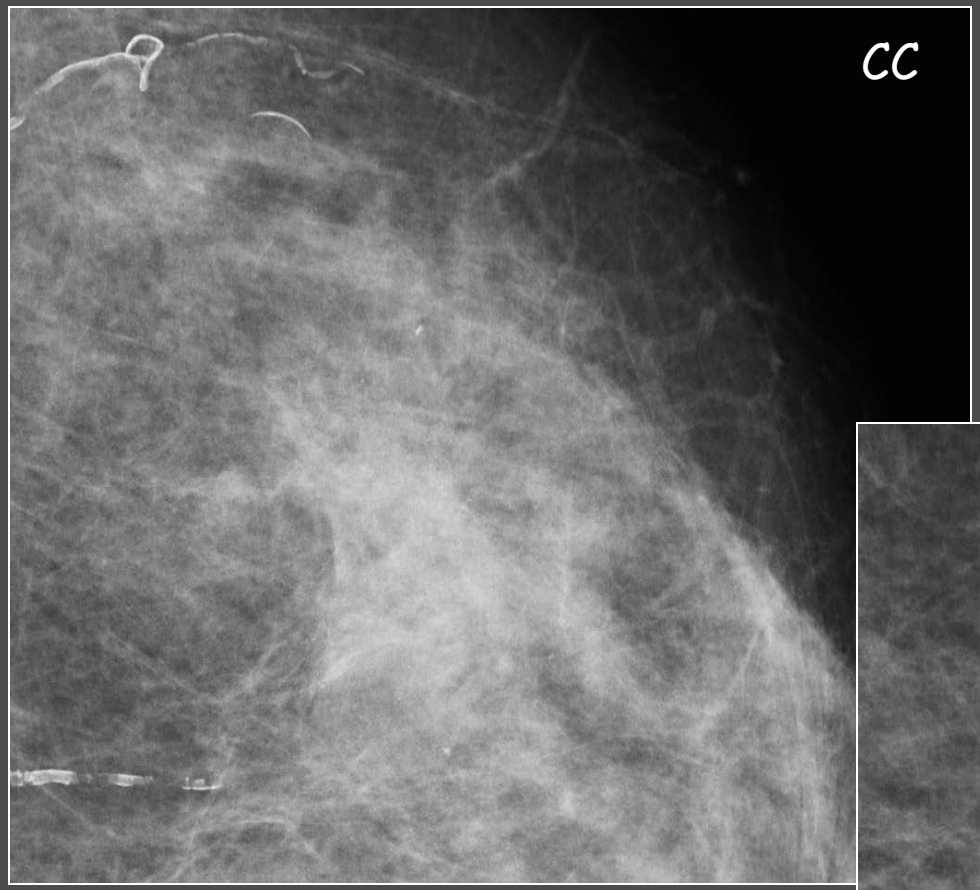

1761-04

AGRANDISSEMENTS

1761-04

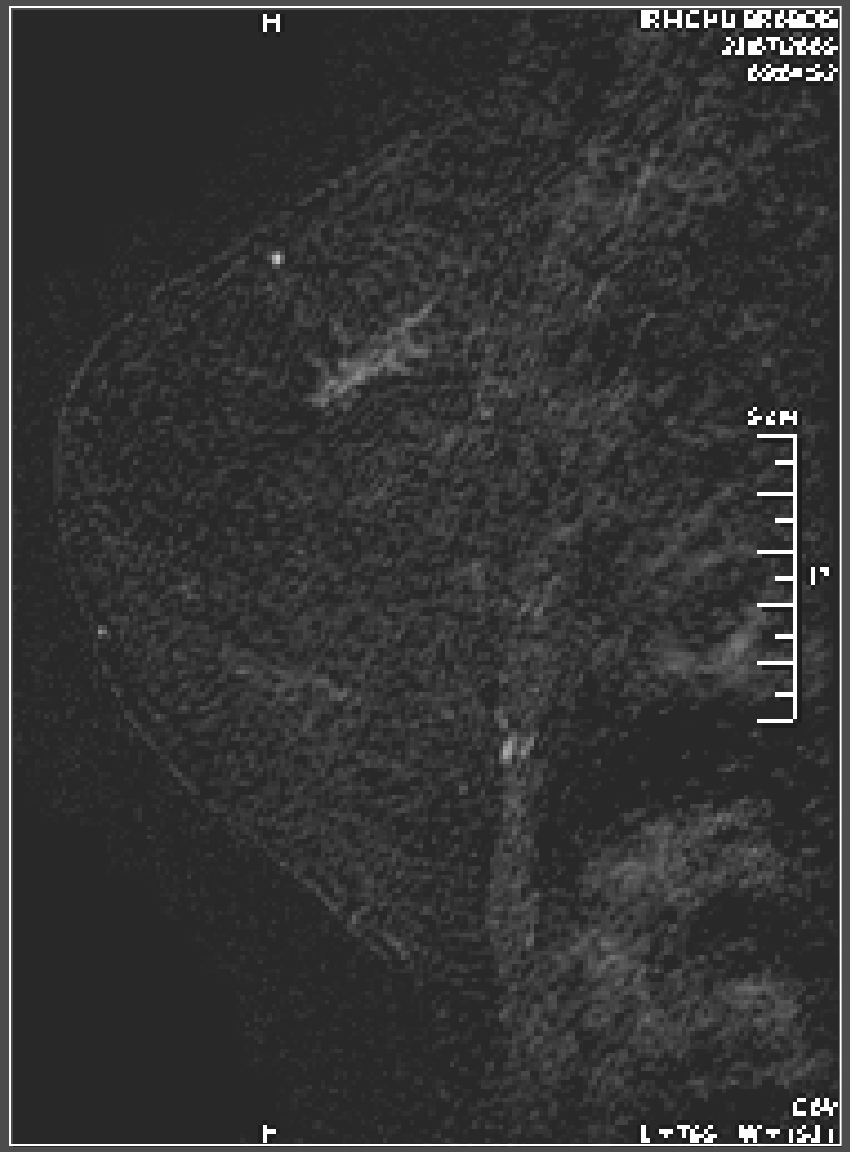

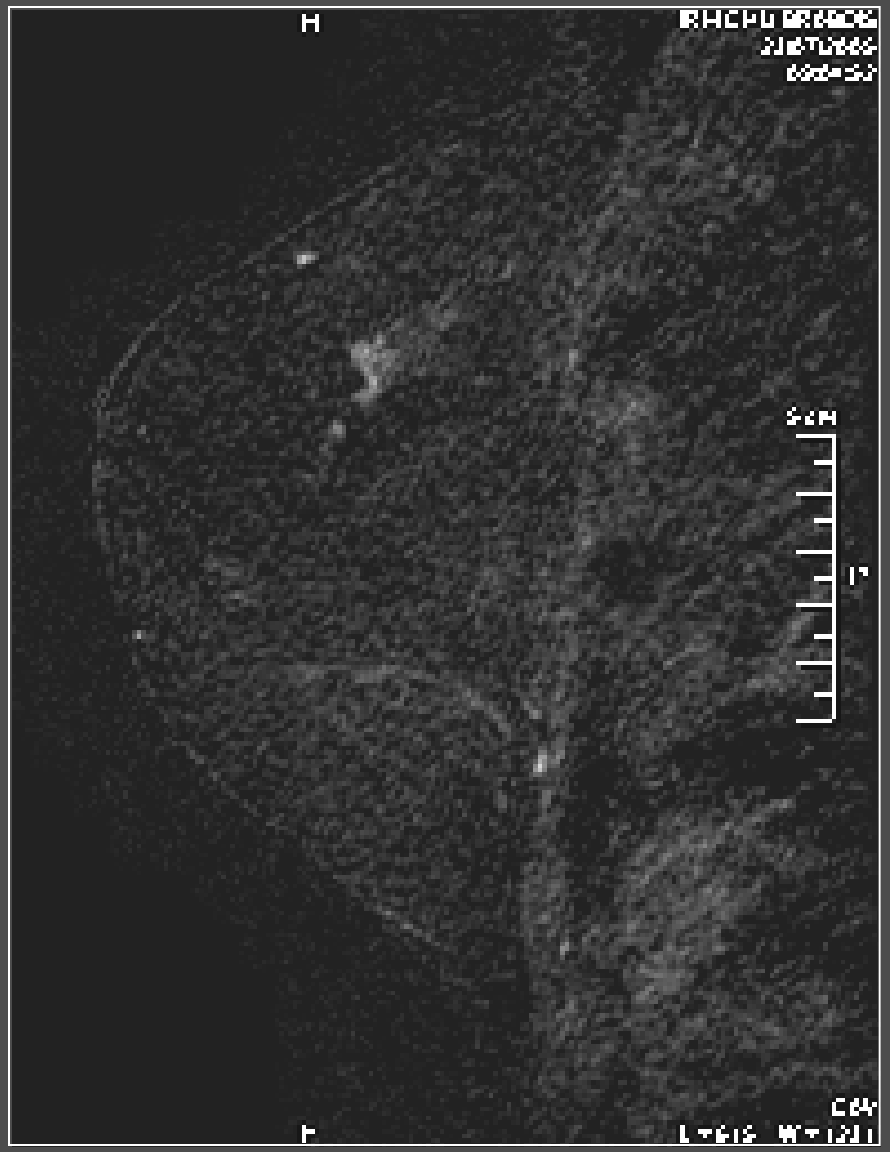

1761-04

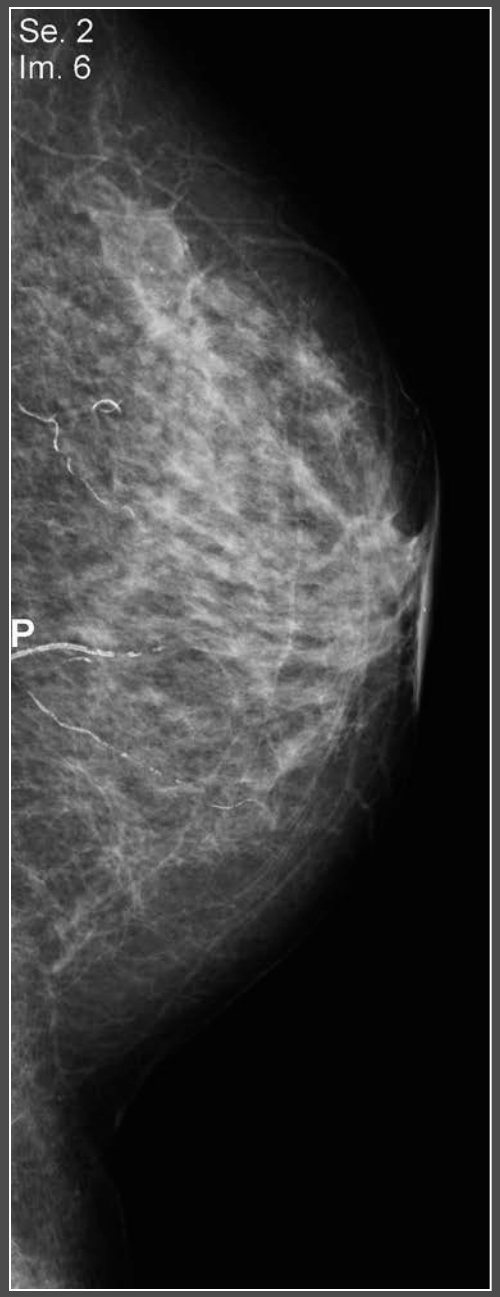

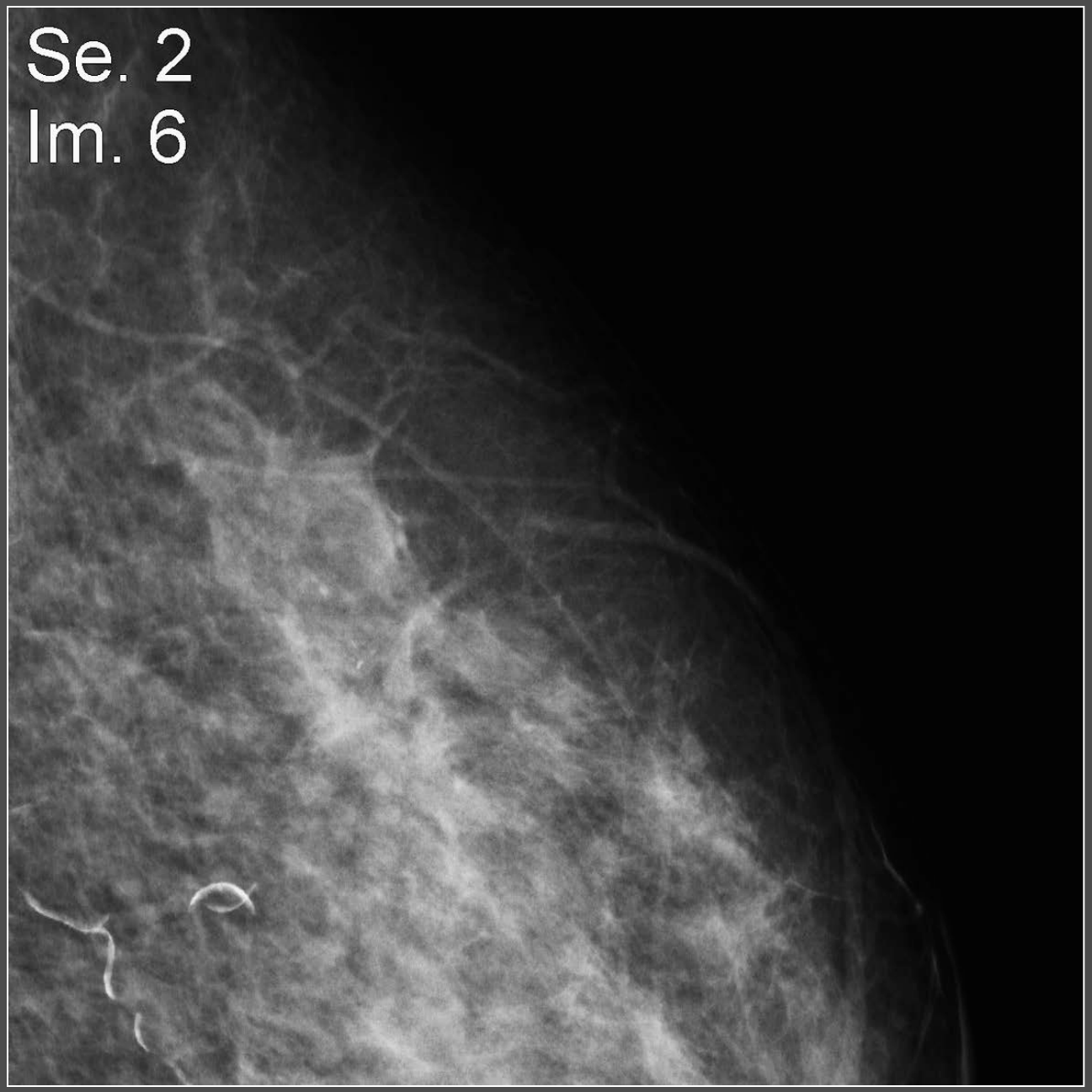

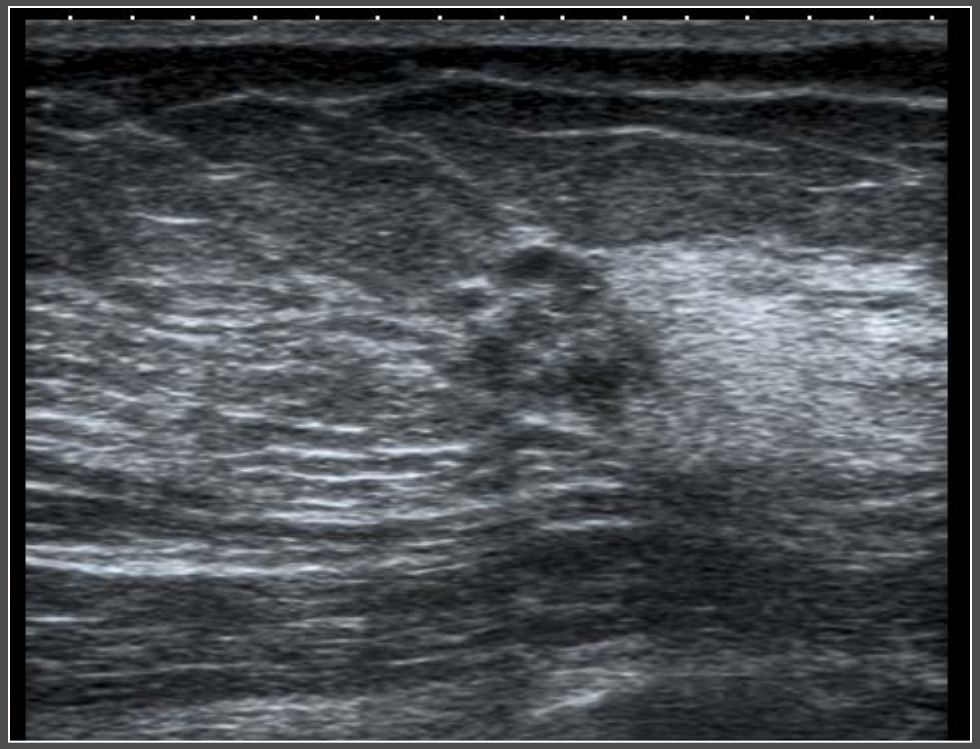

1761-04

-Cytologie sous contrôle échographique : hyperplasie épithéliale mais sans atypies
-Proposition de biopsie chirurgicale

1748-06

- Patiente de 30 ans ayant eu une prothèse d'augmentation bilatérale il y a 12 ans
- Nature de la prothèse non connue
- Masses axillaires bilatérales
- << fibroadénome >> connu du sein G

1748-06

Régions axillaires

1748-06

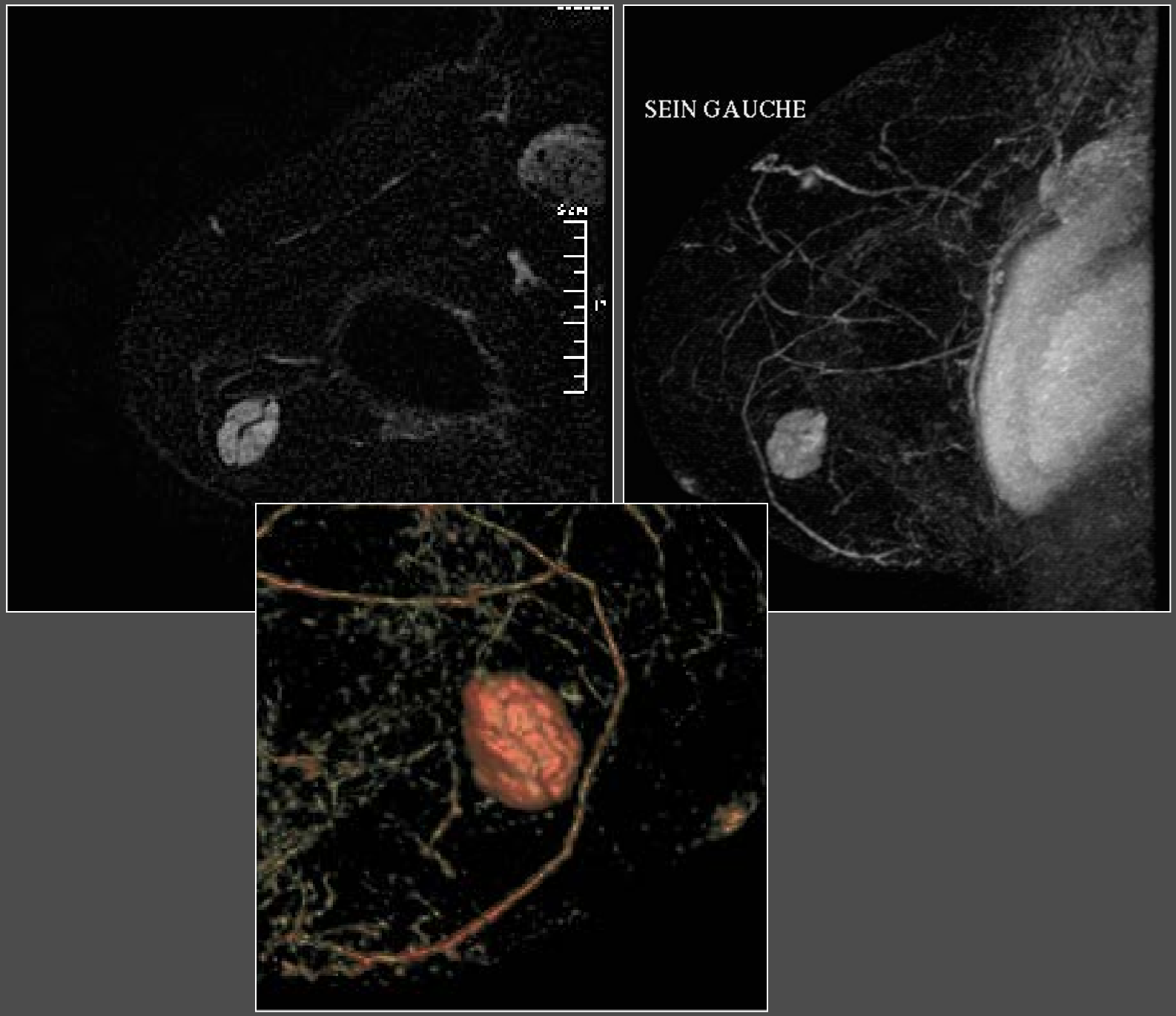

1748-06

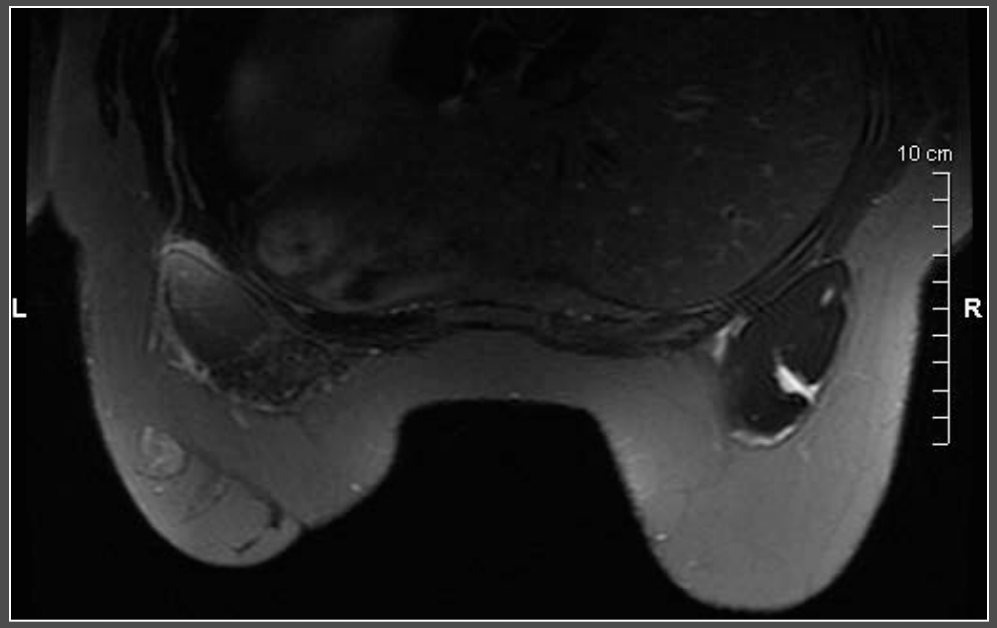

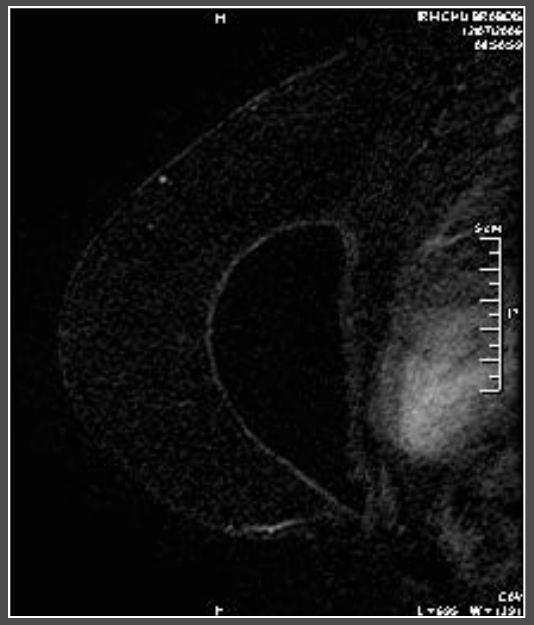

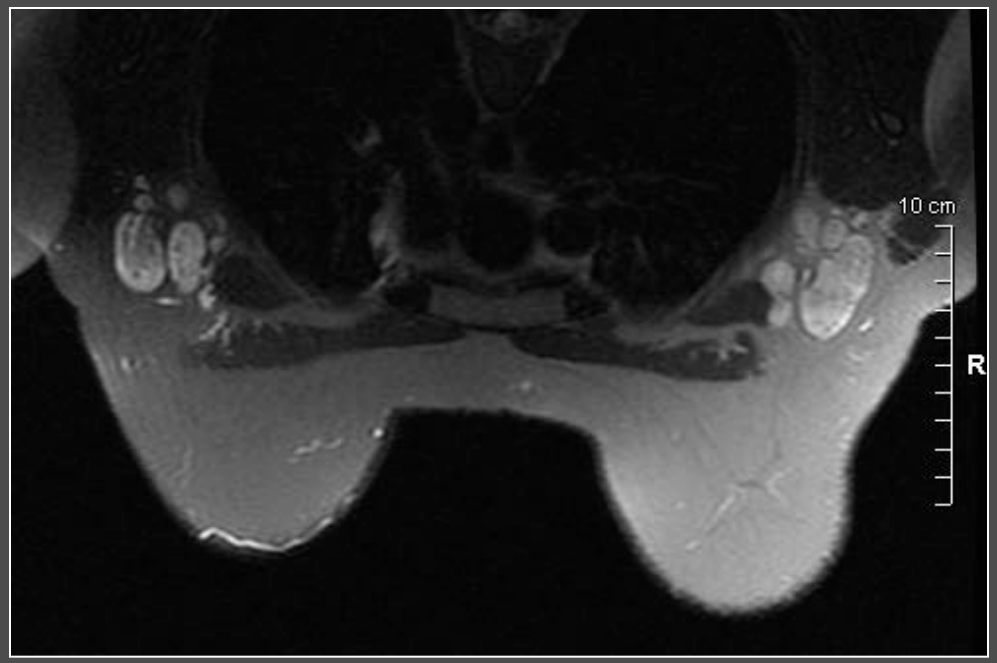

T2

C+ soustraction

1748-06

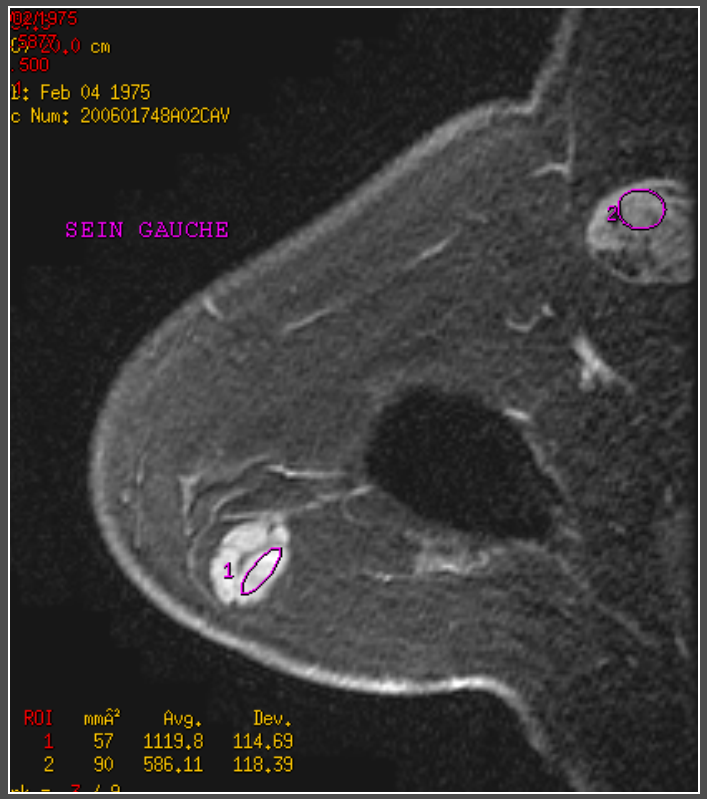
SEIN GAUCHE
Feb 04 1975
Num: 200601748A02CAV
ROI mmÂ² Avg. Dev.
1 57 1119.8 114.69
2 90 586.11 118.39

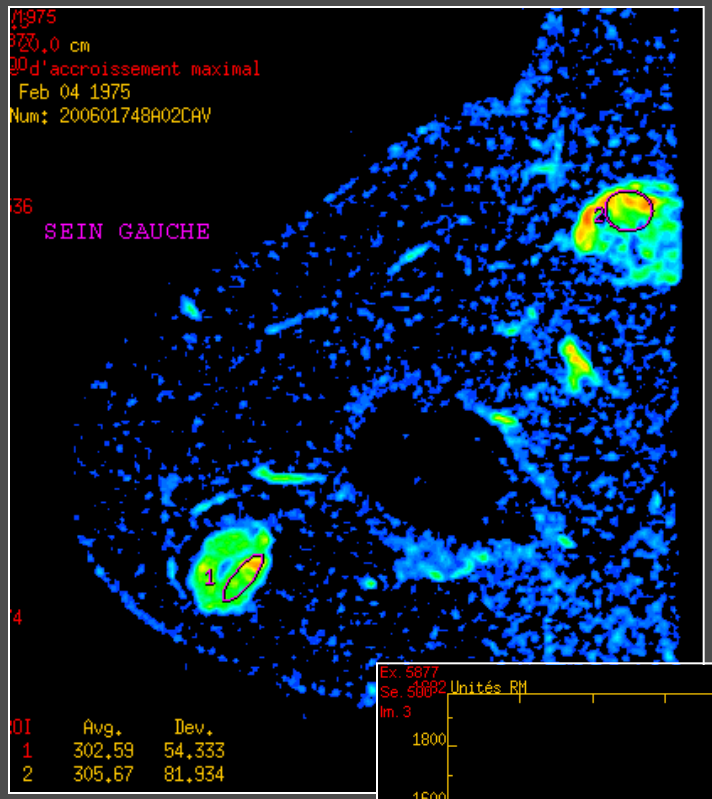
d'accroissement maximal
Feb 04 1975
Num: 200601748A02CAV
SEIN GAUCHE
Avg. Dev.
1 302.59 54.333
2 305.67 81.934

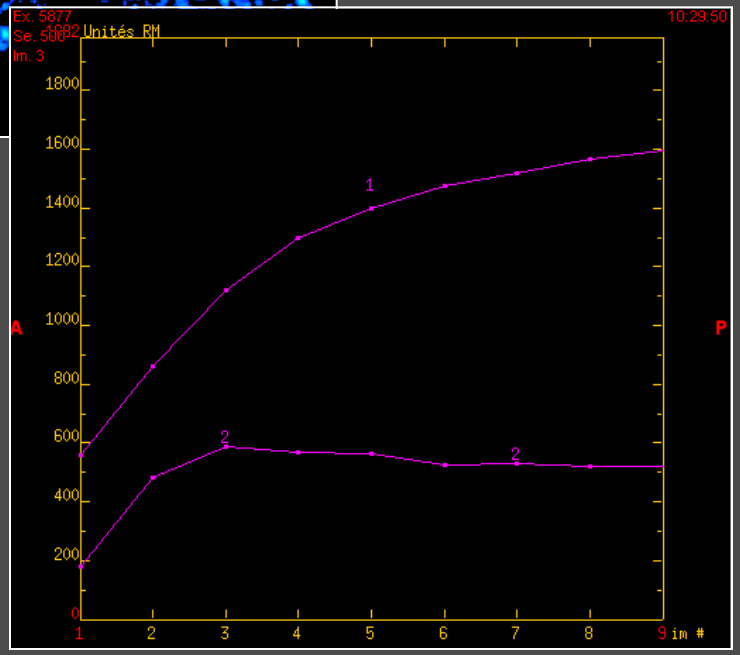
Unités RM
10:29:50
A
P
1800
1600
1400
1200
1000
800
600
400
200
0
1 2 3 4 5 6 7 8 9
im #

1748-06

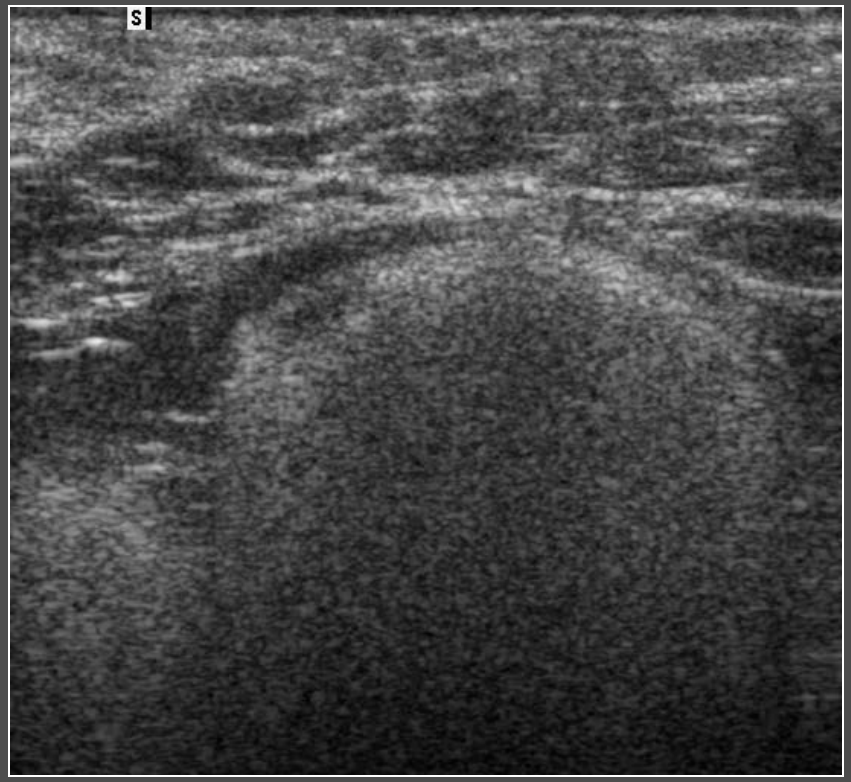

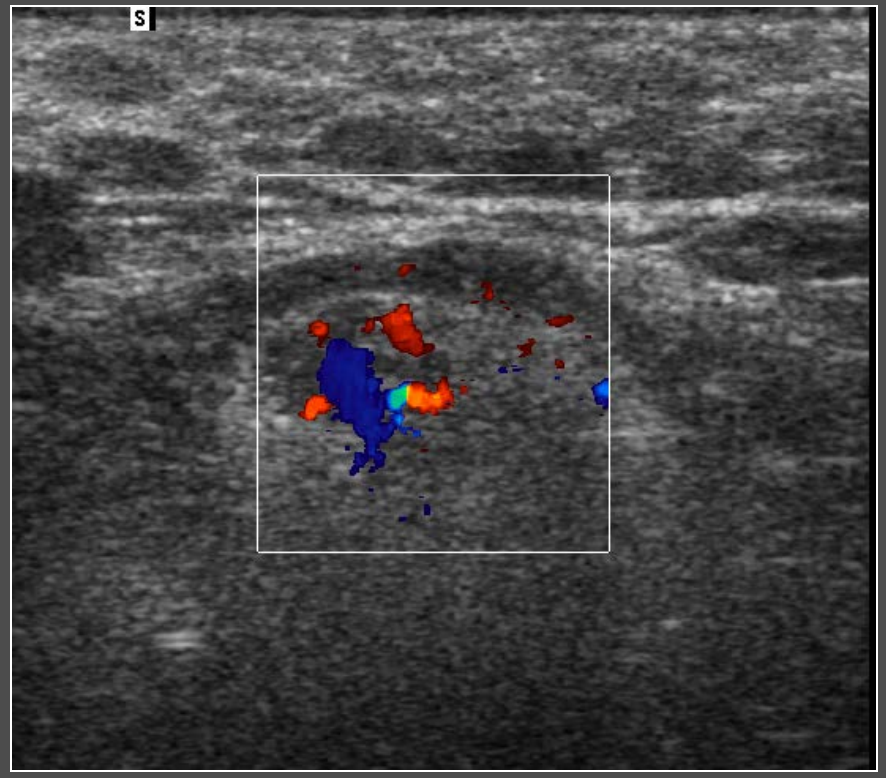

1748-06

- Pas de signe macroscopique de rupture extra-capsulaire
- Adénopathies bilatérales
- Cytologie : Nombreux histiocytes à cytoplasme vacuolisé contenant des corps étrangers réfringents

1748-06

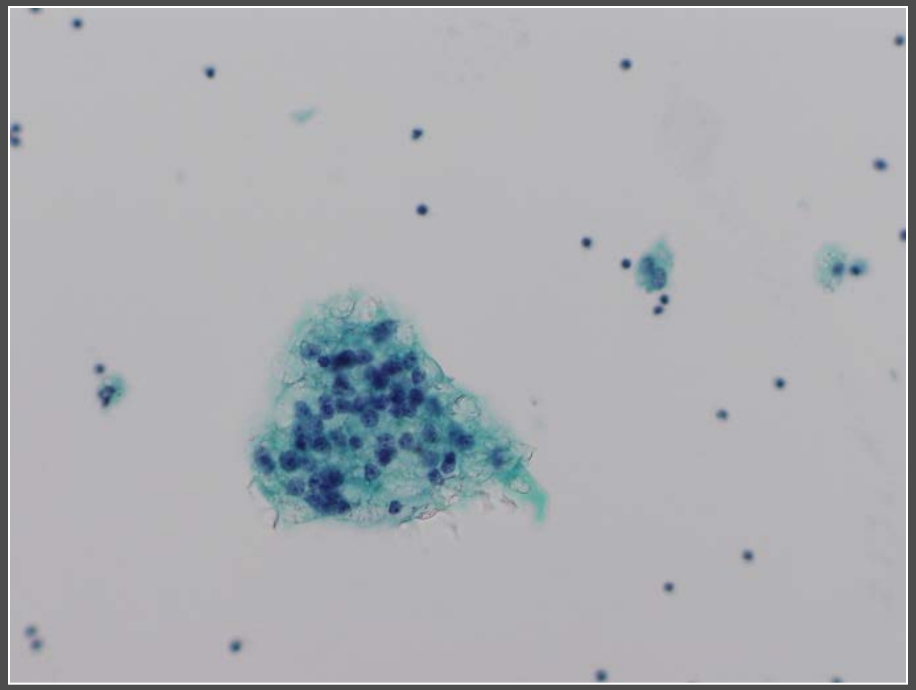

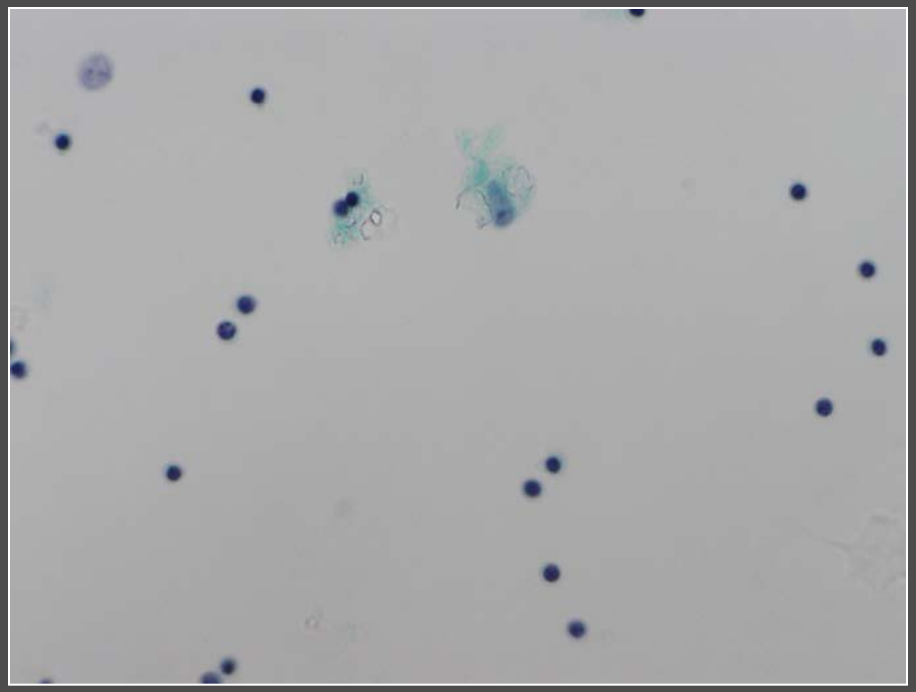

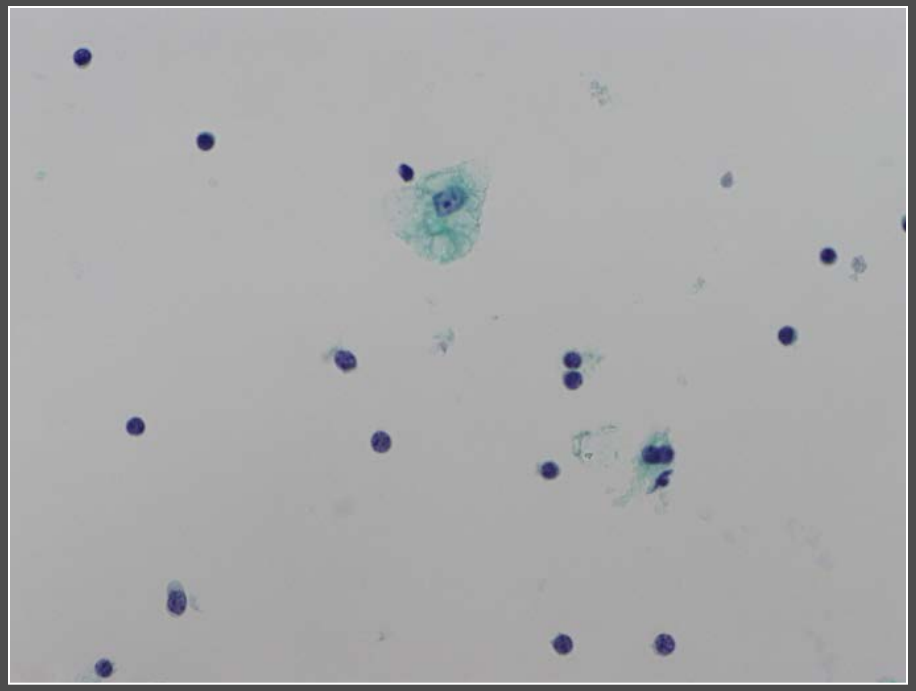

1748-06



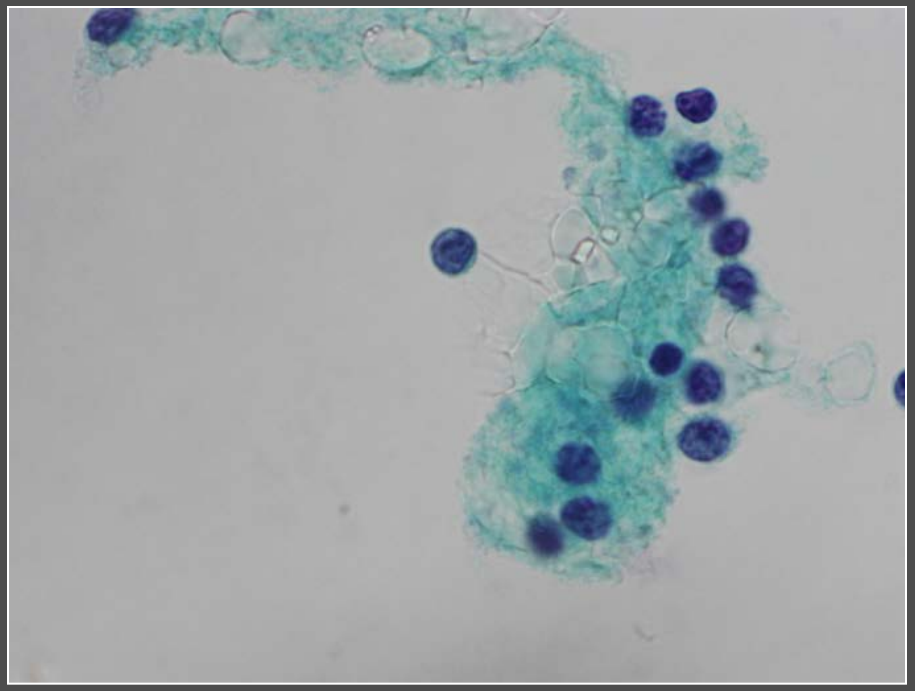

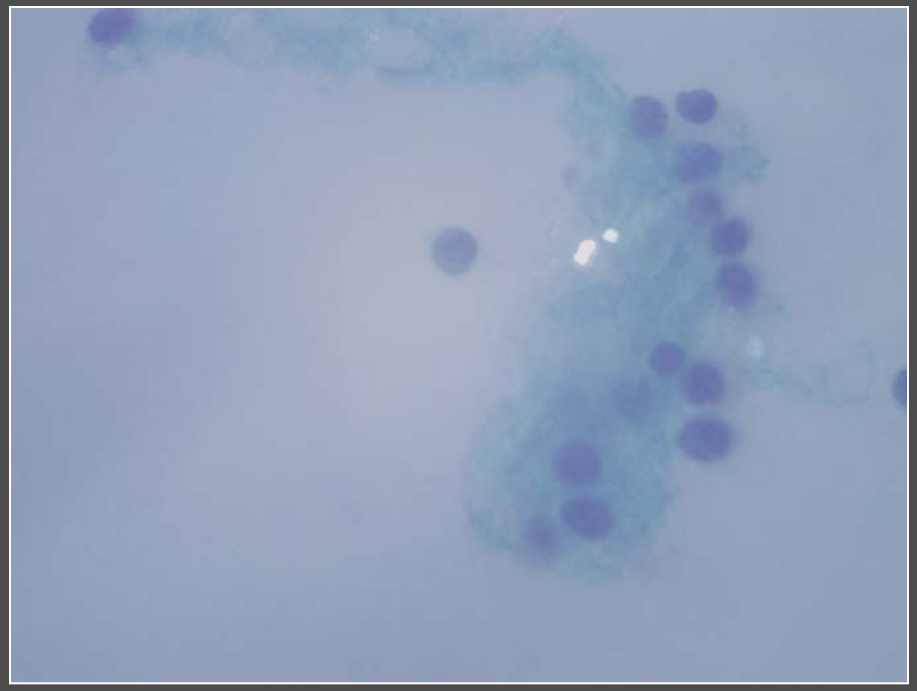

1866-06

- Patiente de 76 ans
- Pas d'antécédent particulier
- Pas de THS
- Examen clinique normal
- Augmentation de microcalcifications du sein D

1866-06

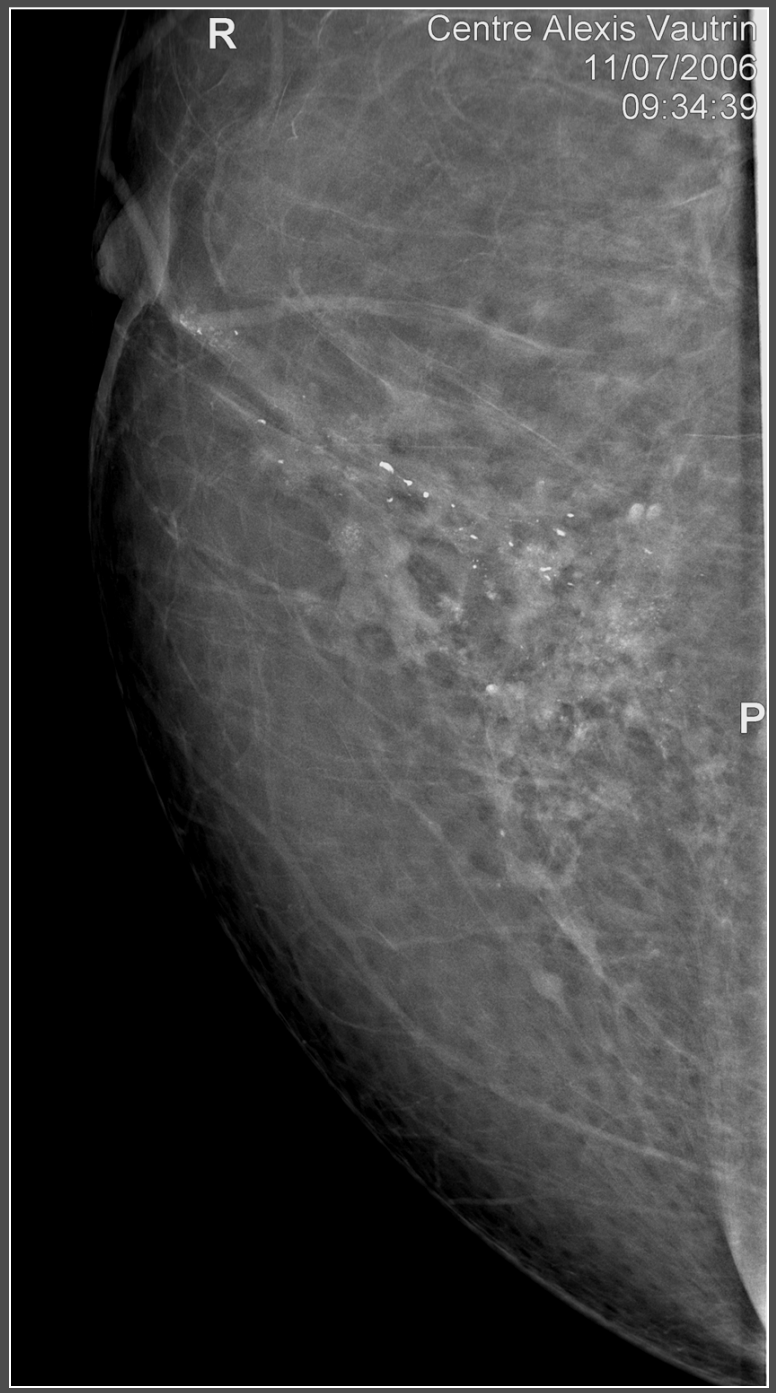
R
Centre Alexis Vautrin
11/07/2006
09:34:39
P

11/07/2006
09:35:56
P

1866-06

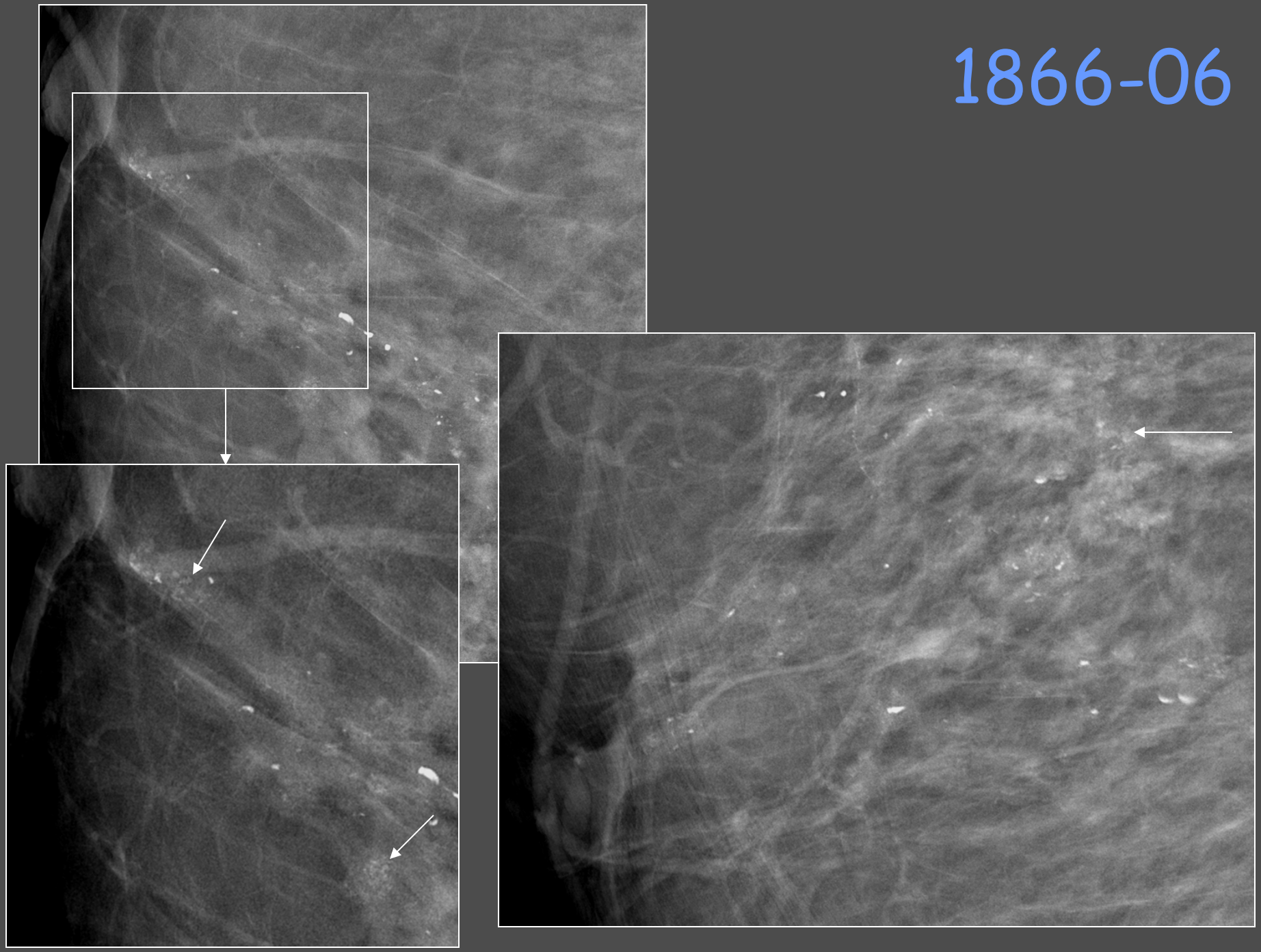

Hypothèse évoquée : association de calcifications bénignes lobulaires et de calcifications liées à des lésions de papillomatose intracanalaire

1605-06

- Patiente de 37 ans
- Antécédents de cancer du sein familiaux (mère, sœur et tante)
- Mammographie à titre systématique

1605-06

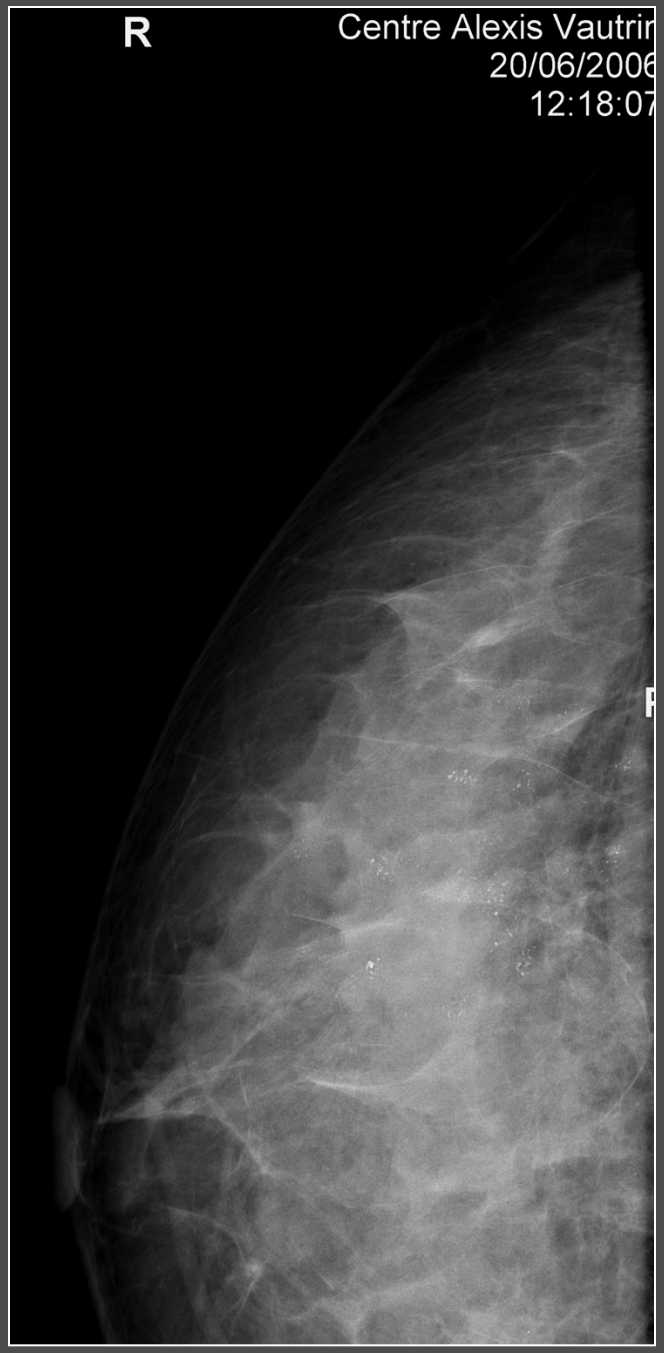
R
Centre Alexis Vautrin
20/06/2006
12:18:07

H
Centre Alexis Vautrin
20/06/2006
12:19:36
F
L = 1455
W = 704

1605-06

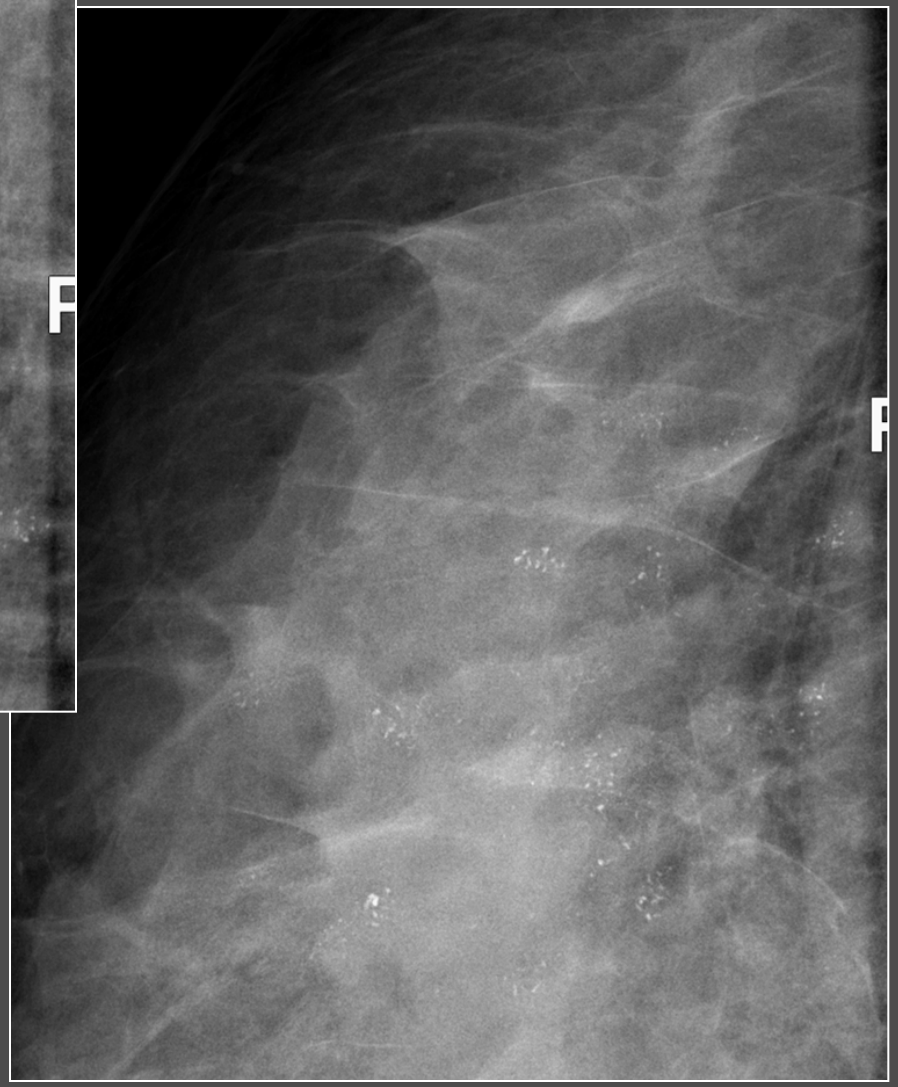

1605-06

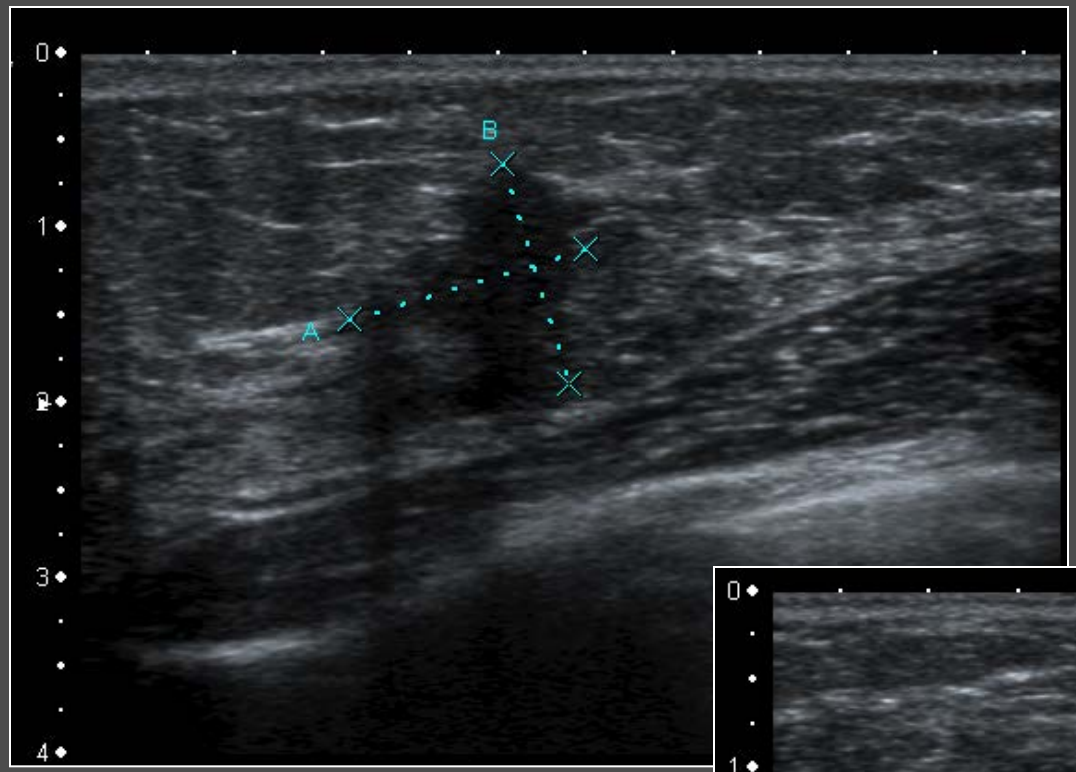

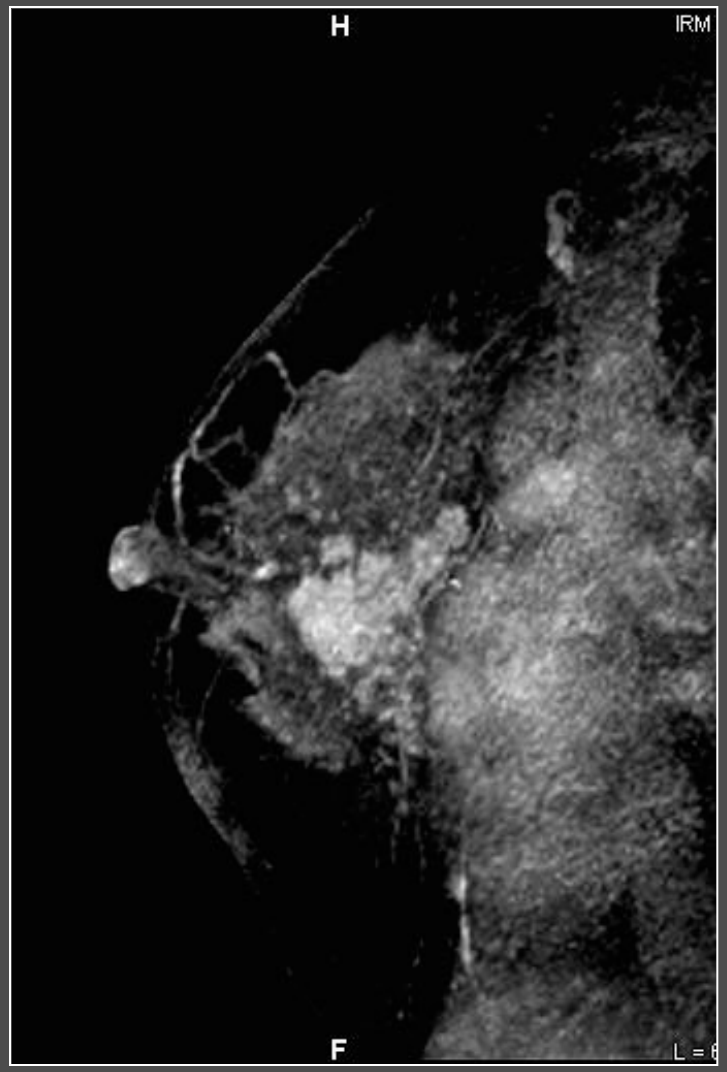
H
IRM
F

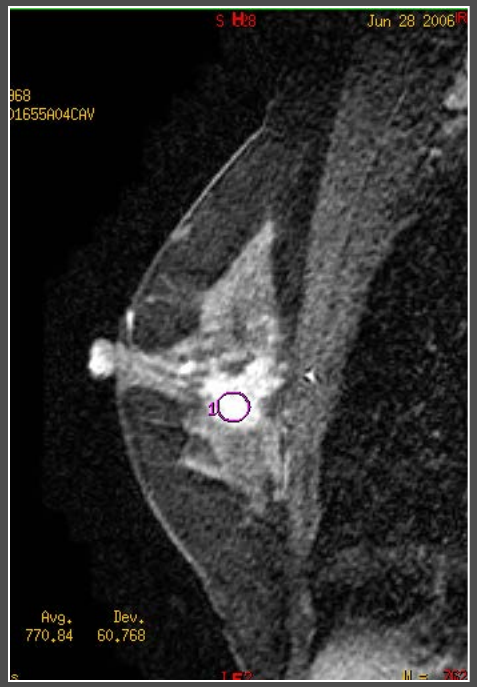
Jun 28 2006
Avg.
770.84
Dev.
60.768

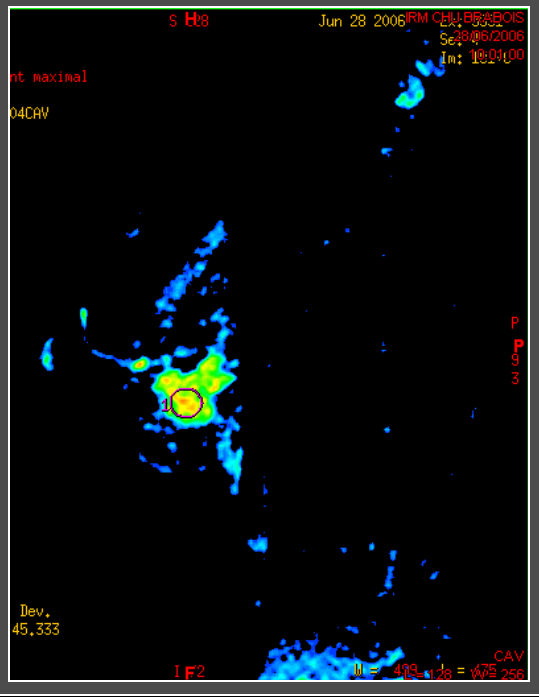
Jun 28 2006
Dev.
45.333

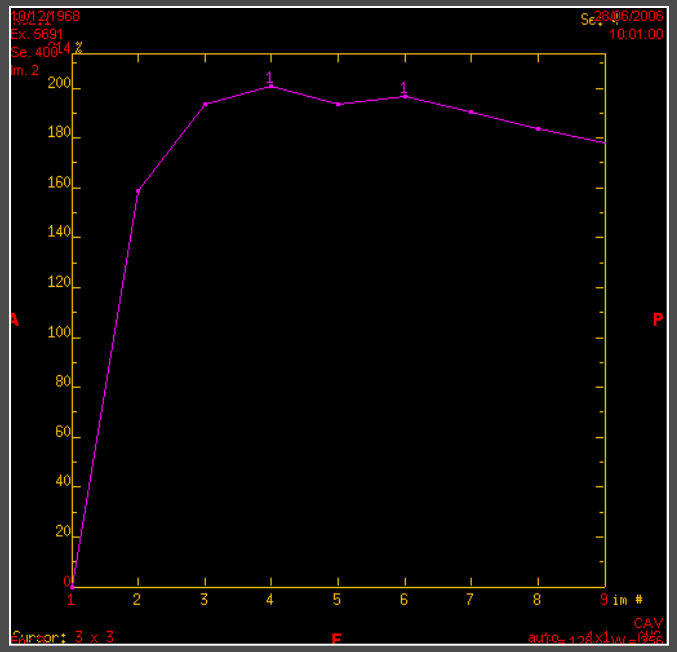
200
180
160
140
120
100
80
60
40
20
0
1
2
3
4
5
6
7
8
9
im #

1605-06

1605-06

Carcinome canalaire infiltrant avec important contingent intracanalaire

1749-06

- Patiente de 73 ans
- Tuméfaction de 1,5 X 1 cm S Int du sein G (ancienne ?)
- Pas d'adénopathie

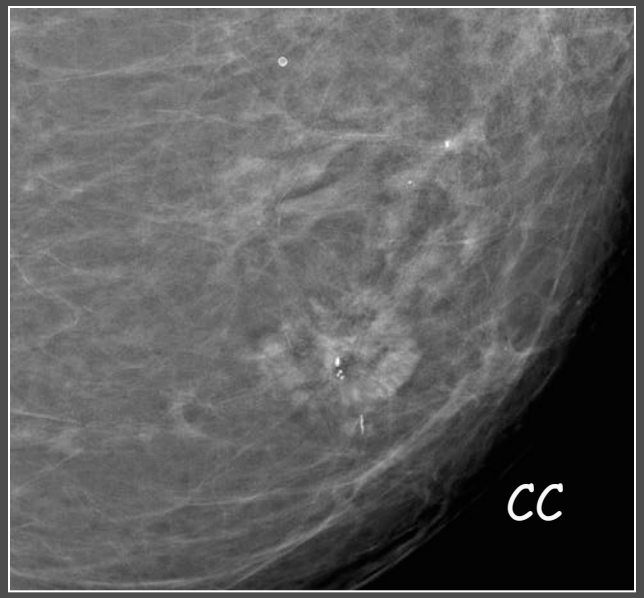

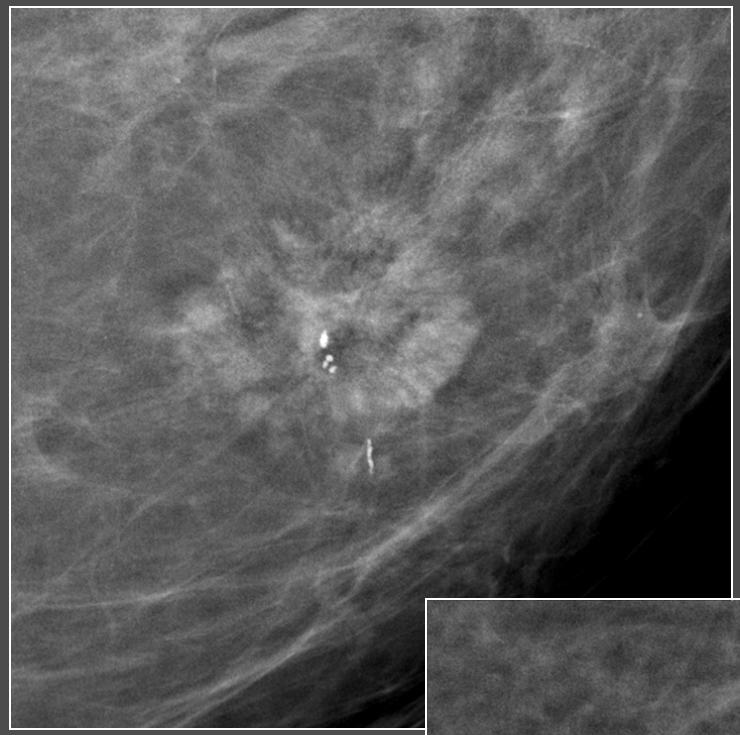

1749-06

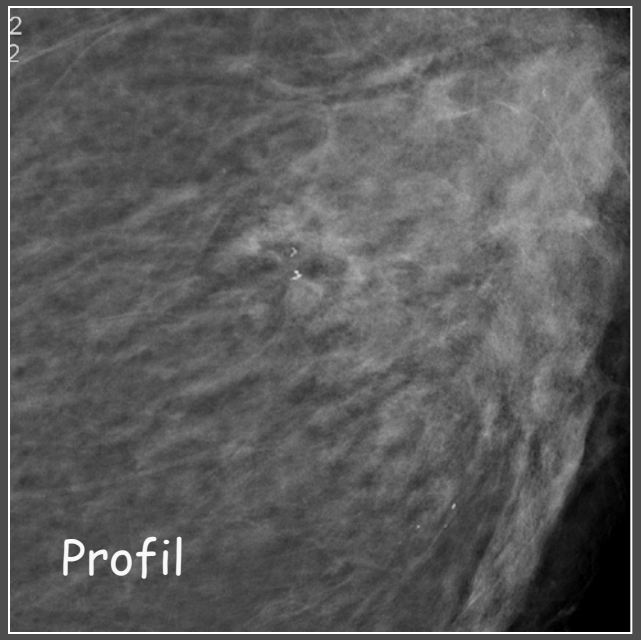

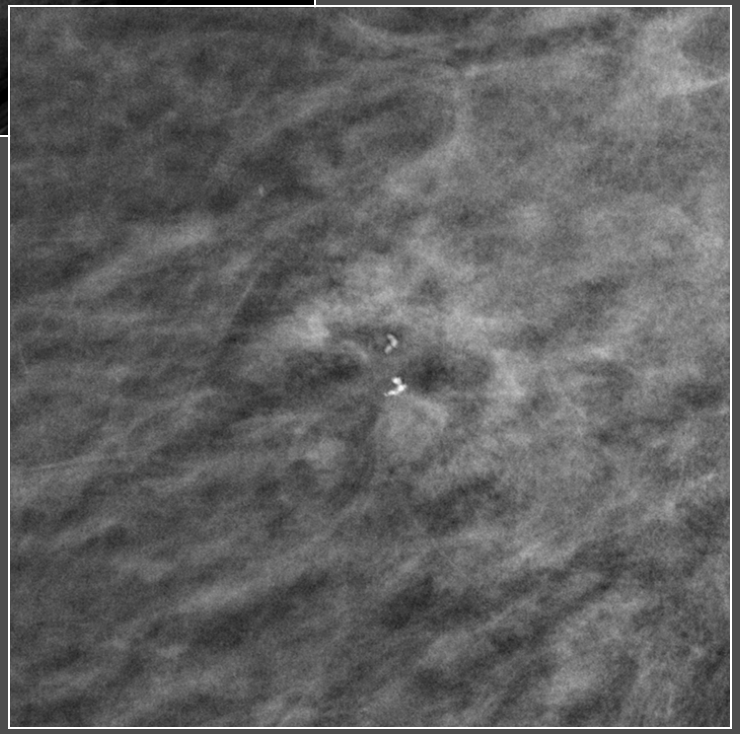

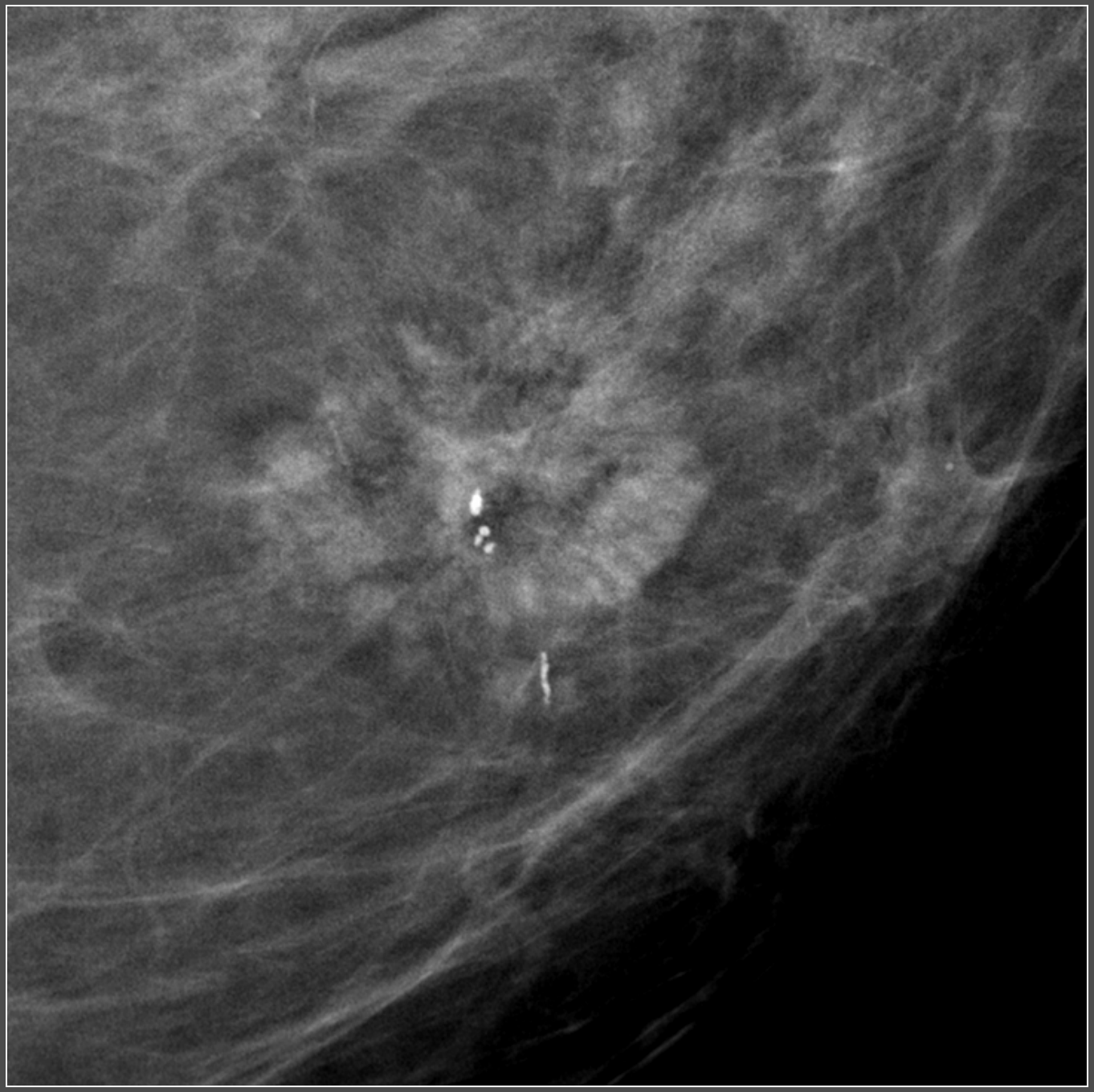

1749-06

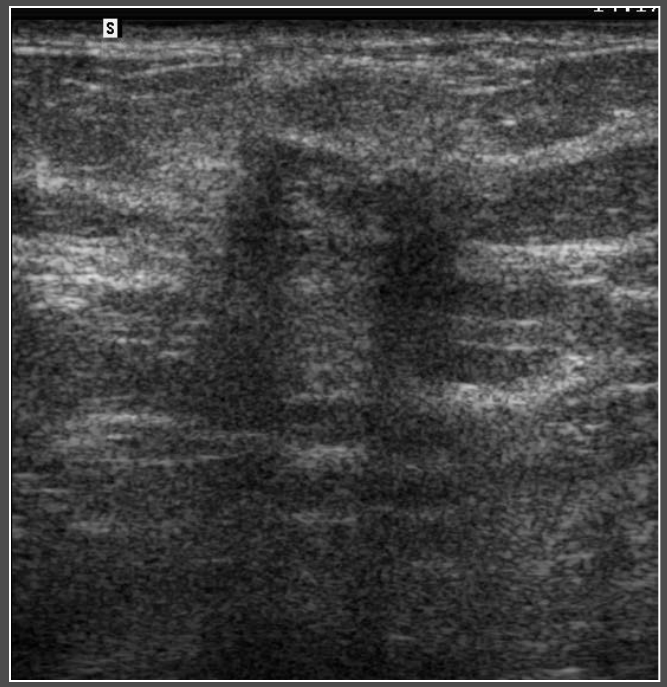

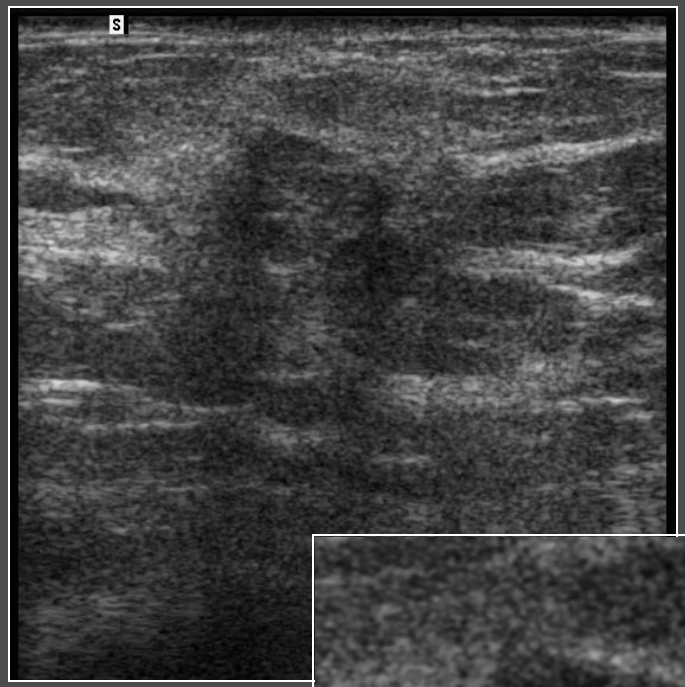

1749-06

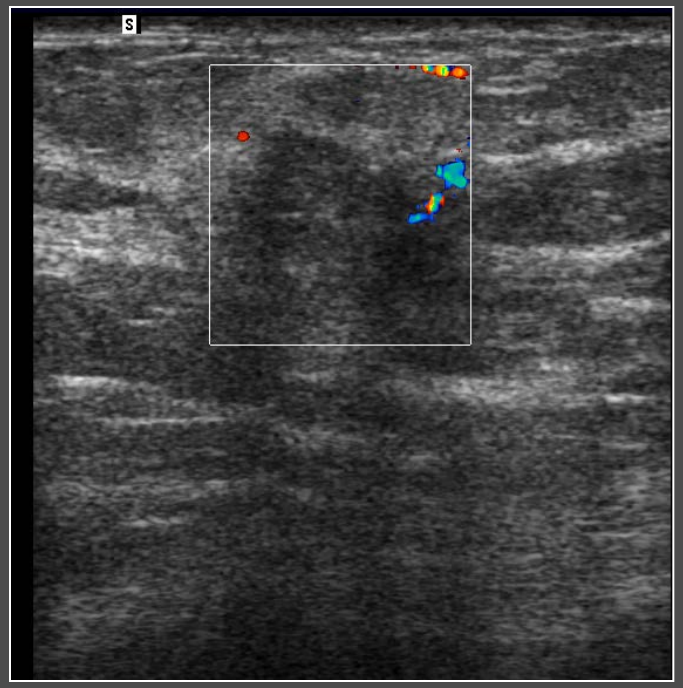

1749-06

CARCINOME A CENTRE CLAIR – PARTIELLEMENT HYPERECHOGENE

CARCINOME CANALAIRE INFILTRANT AVEC STROMA INFLAMMATOIRE ET COMPOSANTE INTRA-CANALAIE

2550-97

- Patiente de 61 ans
- THS
- Pas d'antécédent familial de cancer du sein
- Examen clinique mammaire bilatéral

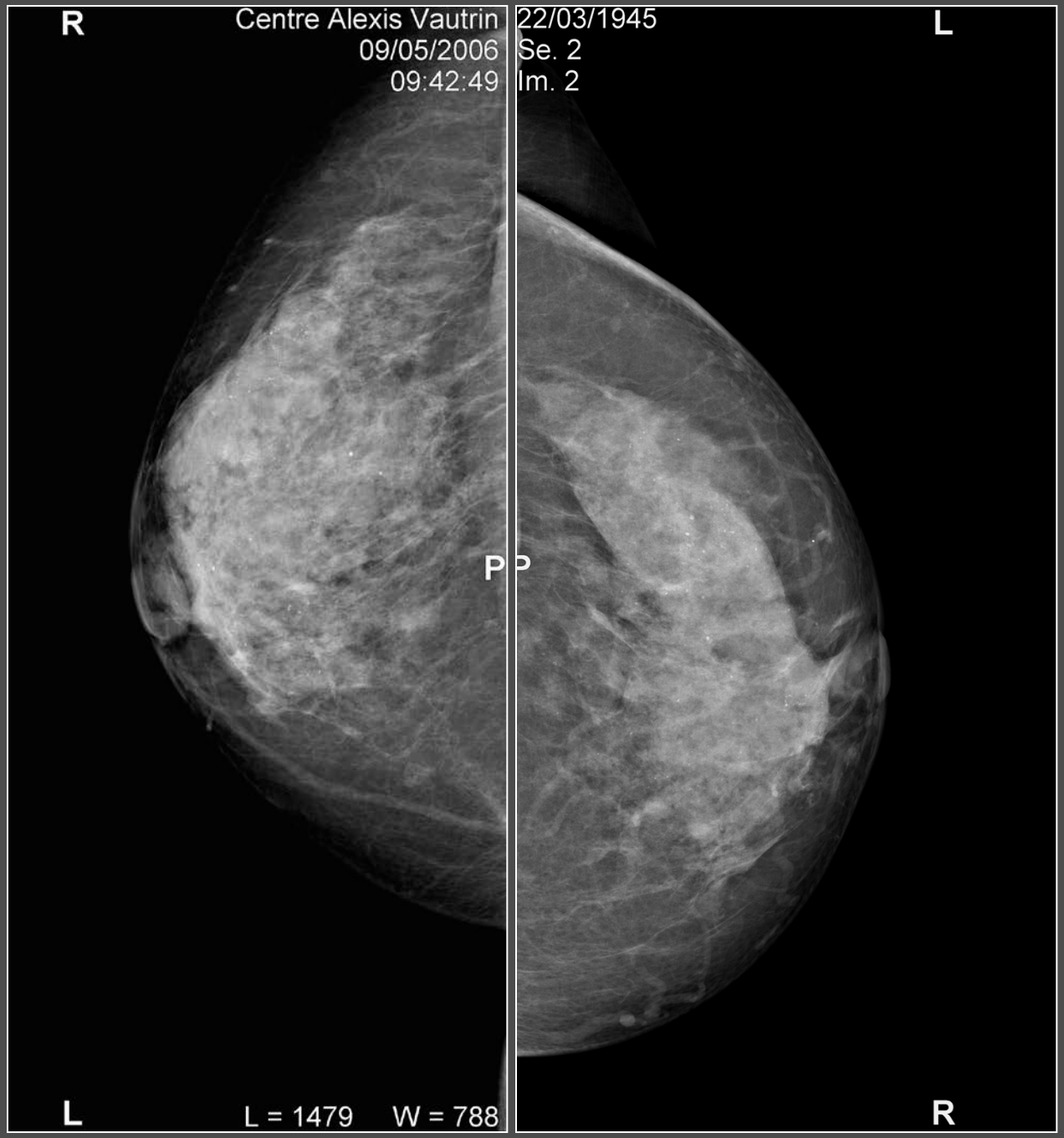
R
Centre Alexis Vautrin
09/05/2006
09:42:49
22/03/1945
Se. 2
Im. 2
L
P
L
L = 1479
W = 788
R

2550-97

HR
Centre Alexis Vautrin
09/05/2006
09:45:47
22/03/1945
Se. 2
Im. 4
HL
P
P
FL
L = 1409
W = 712
FR

2550-97

H
Centre Alexis Vautrin
09/05/2006
09:49:01
22/03/1945
Se. 2
Im. 6
H
P
P
F
L = 1521
W = 710
F

2550-97

2550-97



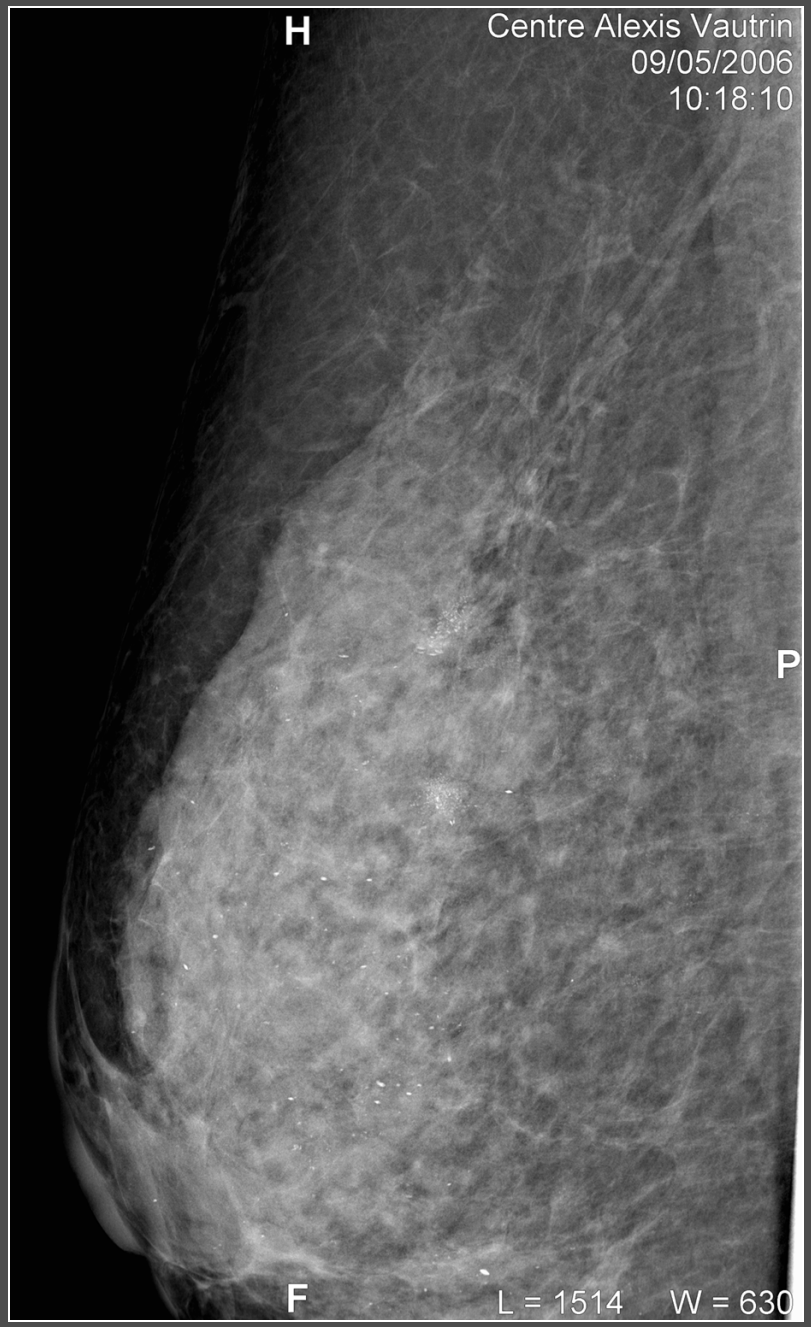

2550-97

Calcifications bénignes
-diffuses
-Weddelite
-sédimentations

2550-97



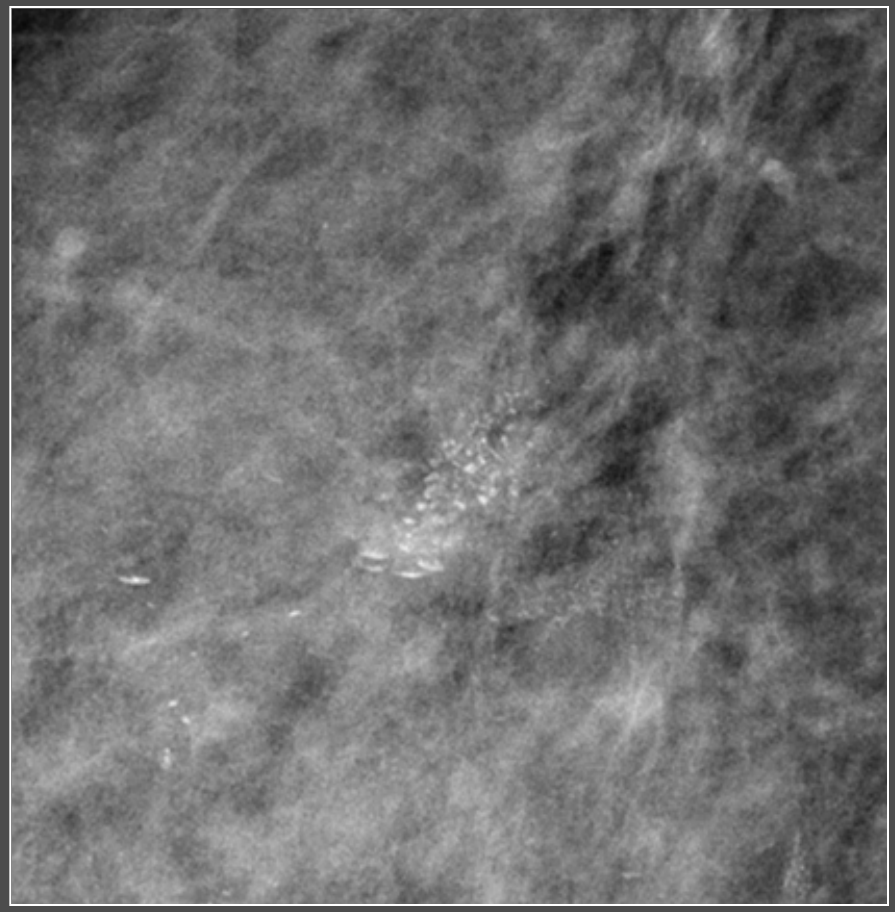

1146-06

- Patiente de 34 ans
- Antécédent de réduction mammaire il y a 2 ans
- Nodule palpable sous la convergence des cicatrices mammaires du sein D

1146-06

1146-06

1146-06

Cytologie : cellules inflammatoires
CYTOSTEATONECROSE POST CHIRURGICALE

1637-06

- Patiente de 51 ans
- Ménopausée sans THS
- Examen clinique normal
- Pas d'antécédent de carcinome mammaire familial
- Mammographie de dépistage
- Microcalcifications mieux visibles au dernier bilan

1637-06

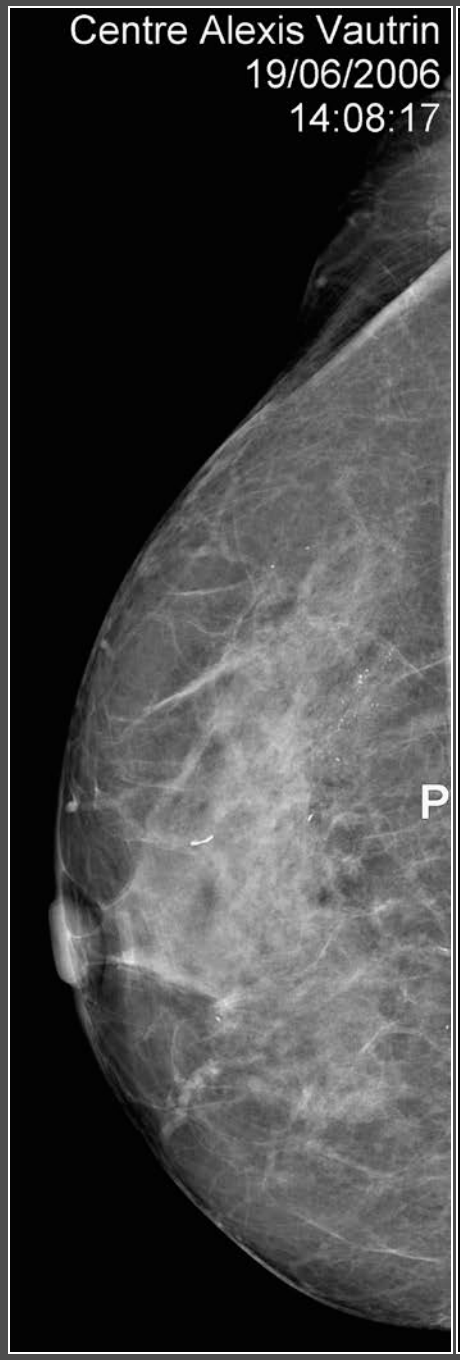
Centre Alexis Vautrin
19/06/2006
14:08:17
P

H
Centre Alexis Vautrin
19/06/2006
14:09:34
P
F
L = 1588
W = 558

P

P

1637-06

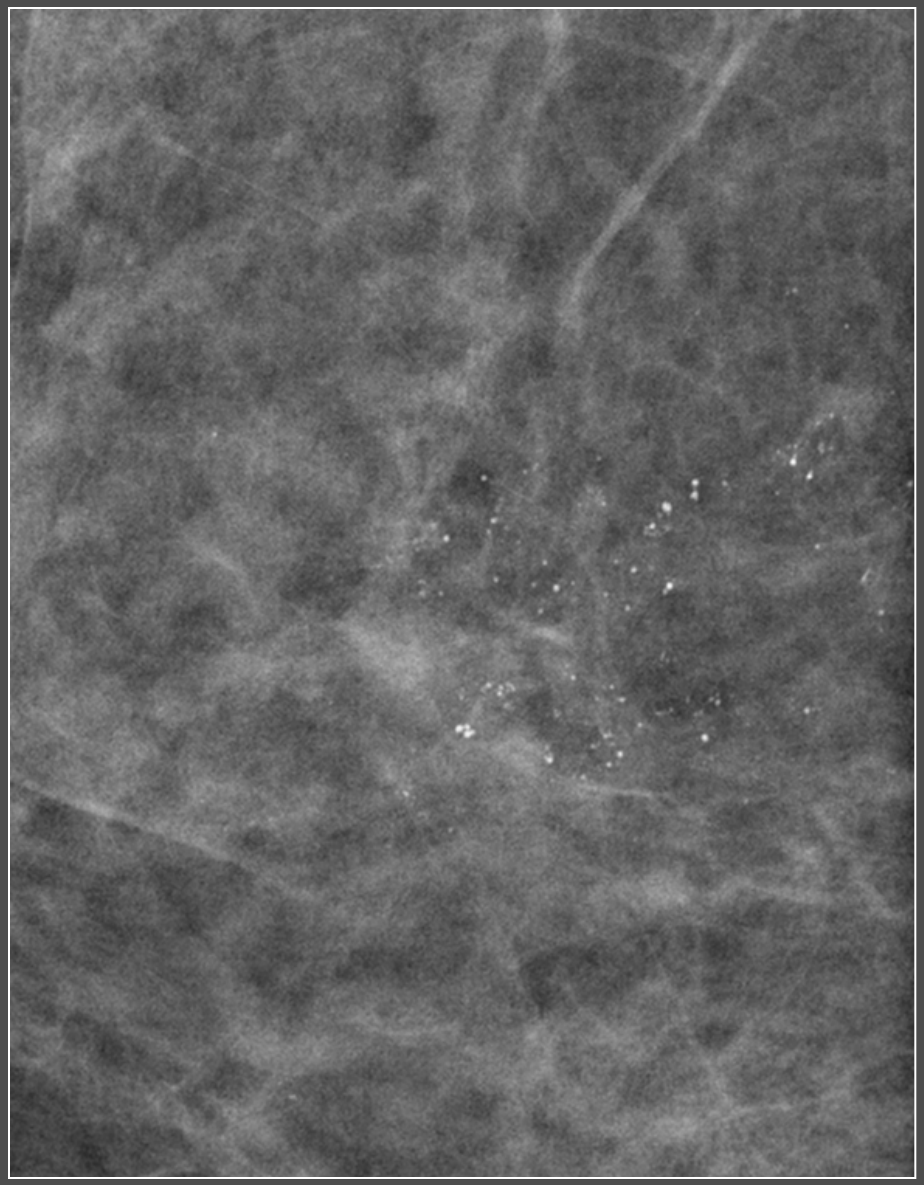

1637-06

MAMMOTOME

1512-06

- Patiente de 35 ans
- Pas d'antécédent particulier
- Examen clinique normal
- Première mammographie de « dépistage »
- Découverte de microcalcifications du sein D

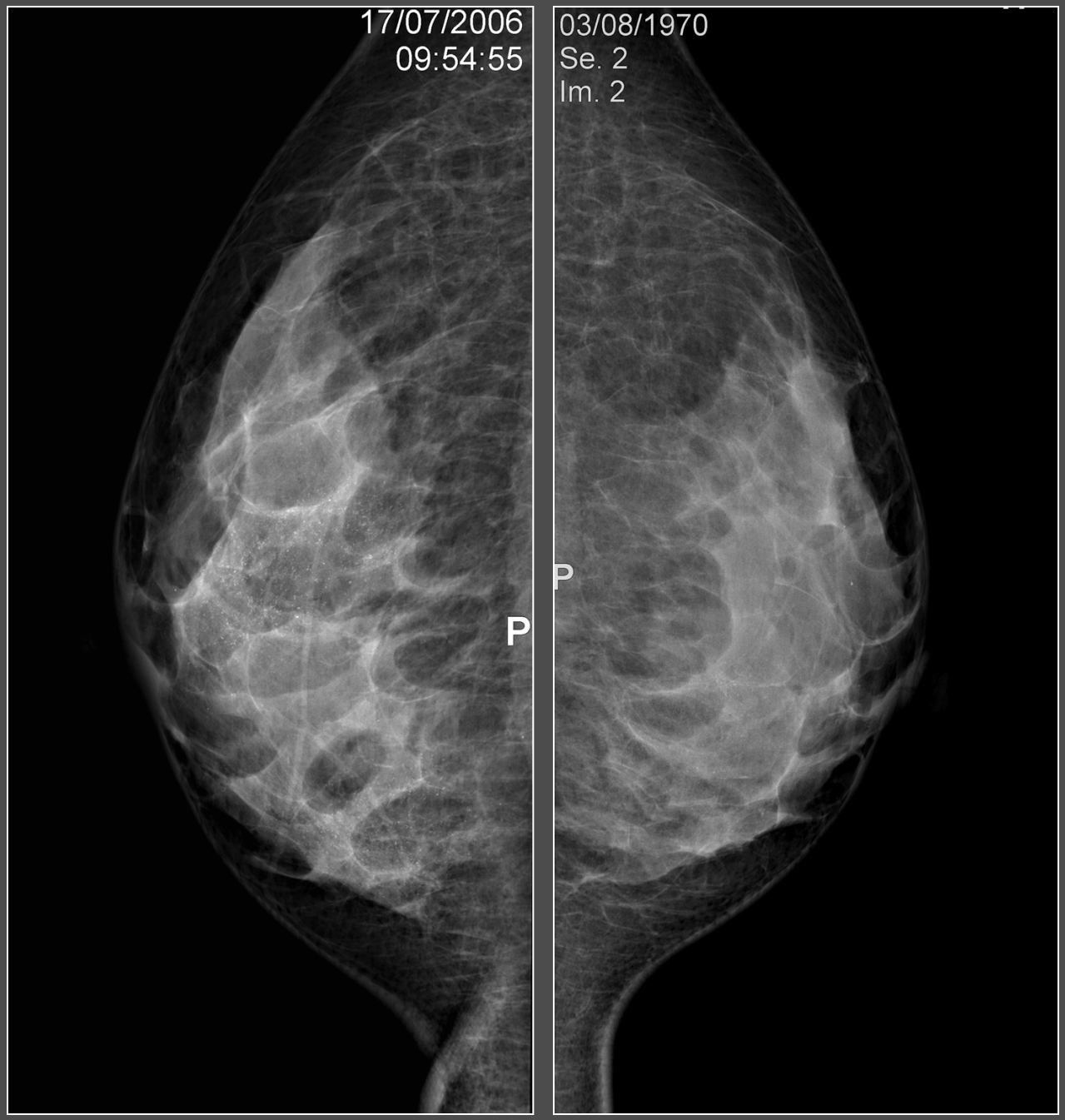

1512-06

1512-06

Prélèvements par Mammotome :